

Idiopathic macular hole: post-operative morpho-functional assessment and prognostic factors for recovery of visual acuity

Flavio Tirelli, Paola Sasso and Andrea Scupola

Dipartimento di Oftalmologia, Università Cattolica del Sacro Cuore, Rome, Italy

Abstract

Introduction. Idiopathic macular hole (MH) is a full-thickness retinal damage typical of the advanced age with a high social impact because, as it affects the macula, it produces severe loss of vision.

Aim. This study aims to evaluate the therapeutic efficacy of surgery and to determine prognostic factors, considering how hypovision weighs on individual quality of life and on public health.

Methods. All patients affected by MH were evaluated with an ophthalmic visit, measurement of visual acuity and Optical Coherence Tomography (OCT) documentation before surgical intervention. Surgical treatment followed and, subsequently, all the patients were examined with the same documentation at 7 days, 1 month, 3 months, 6 months and 12 months.

Results. Surgical therapy, with the modern techniques available, demonstrated the efficacy of anatomical recovery and retinal function. Furthermore, the quantitative characteristics of the MH in the OCT scanning revealed an important prognostic function.

Key words

- macular hole
- optical coherence tomography (OCT)
- visual outcome

INTRODUCTION

Ophthalmic pathologies in general, and those affecting the retina in particular, are of considerable concern on account of their potential damage and because of the well documented social impact of blindness and hypovision on the population and the marked deterioration in quality of life.

Idiopathic macular hole is a full-thickness break or defect in the macula that involves all layers of the inner limiting membrane to the photoreceptors, causing centrifugal displacement of the central dehiscence of the umbo [1] (Figure 1). The primary event is probably an anomalous vitreofoveal attachment, leading to anterior-posterior traction of the posterior hyaloid and tangential traction of the internal limiting membrane [2].

Macular holes are more commonly found in women (72% of cases) and in subjects aged between 65 and 74 [3]. The risk in these patients of the other eye being affected has risen compared to the general population, and is in the area of 10-15%. The pathology presents as seriously impaired central vision with metamorphopsia and blurred central vision that may appear suddenly or progressively and can lead to loss of central visual acuity [1].

Optical Coherence Tomography (OCT) has made it possible to describe and analyse all the layers of the

retina with extreme precision and has become a fundamental instrument in numerous retinal pathologies. OCT is a very reliable method with high resolution and its non-invasive nature allows it to be used repeatedly during each stage of diseases. It is especially important in the study of macular holes and in identifying their various stages as classified by Gass.

In the first stage there is usually an intraretinal break or a localised cyst in the inner retinal layer and centripetal tangential traction of the prefoveal vitreous. The photoreceptor layer may also be raised [7, 8].

In the second stage OCT shows a major separation of the photoreceptor layer and an incomplete opening of the operculum, to which the posterior hyaloid is still attached: cystic spaces are also visible on the periphery of the hole [7]. In the third stage the retina is raised and slightly thickened, with cysts surrounding the hole. The separation of the vitreous is often revealed by the presence of the operculum, which at OCT appears hyper-reflective. White deposits may also be visible on the surface of the retinal pigment epithelium (RPE) at the base of the hole, representing nodular proliferations of RPE cells.

The only difference between the third and fourth stages is the size of the hole, which is larger in the latter [9].

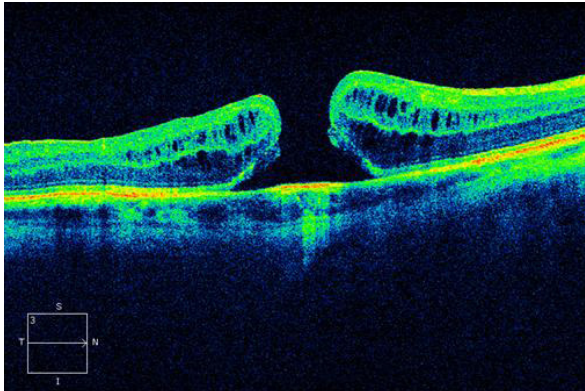


Figure 1
OCT image of full-thickness macular hole.

OCT has considerably improved visualisation of the individual layers of the retina, making it possible to examine in greater detail the layer joining the inner and outer segments of the photoreceptors and the outer limiting membrane. Numerous studies have shown that the continuity of the external limiting membrane (ELM) and the integrity of the inner segment/outer segment (IS/OS) junction are strongly correlated with post-operative visual recovery in patients undergoing surgery for macular hole. Specifically, it has been demonstrated that interruptions of the IS/OS junction, which indicate an anatomical misalignment of the outer segment, are correlated with poorer visual recovery. Recently, however, the continuity of the ELM has been identified as the principal prognostic indicator of visual acuity recovery [10].

Recent improvements in surgical techniques and in results, accompanied by a decrease in complications associated with vitreoretinal surgery, make surgery for affected eyes recommendable.

The intervention envisages vitrectomy *via pars plana*, removal of the internal limiting membrane formerly having evidence it with colouring, followed by fluid-air exchange. The air is then replaced with a non-expandable gas whose duration of action varies according to the type of gas used: a shorter acting gas (sulphur hexafluoride, SF₆) or longer acting gas (or perfluoropropane, C₃F₈).

Recent studies have investigated the use of peeling of the internal limiting membrane (ILM), and suggest that removal of the ILM increases the rate of closure of macular holes and may also improve final visual acuity [11]. Intraoperative visualisation of the ILM can be facilitated using Indocyanine green, Membrane Peel, Trypan blue or Triamcinolone acetonide.

Numerous authors have studied the importance of the face-down position to be maintained by patients for at least one week after the operation, meaning that the patient must keep his/her head facing downwards for some hours during the day and the night so that the gas injected into the eyeball can tampon the macular region. Holding the head in this position appears to increase the success rate of macular hole treatment, although some authors have suggested that keeping the face-down position only for the first two post-operative days is enough to obtain the desired result [12, 13].

PATIENTS AND METHODS

We examined and surgically treated 23 eyes of 23 patients with idiopathic macular hole. Patients were selected in accordance with the following inclusion criteria: diagnosis of idiopathic macular hole with onset < 1 year and vision > 1/10; and the following exclusion criteria: serious dysmetabolic or autoimmune diseases, previous cardiovascular or cerebrovascular pathologies, diagnosis of macular hole of traumatic or myopic origin, significant dioptric media opacity.

The patients underwent *pars plana* vitrectomy, removal of the ILM, BSS/air/sulphur hexafluoride (SF₆) exchange. Adjuvants for visualisation of the ILM were also used; specifically either Membrane Peel or Triamcinolone acetonide.

Patients were urged to maintain the face down position for the first 7 days in order to allow the injected gas to act as a tampon on the macular region: a shorter-acting gas was used.

All patients were given a complete ophthalmological assessment prior to treatment and 7 days and 1, 3, 6 and 12 months after it.

Long distance visual acuity in accordance with standard ETDRS (Early Treatment Diabetic Retinopathy Study) protocols using a modified ETDRS chart at 4 metres (Precision Vision, Bloomington, IL), near-sighted vision assessment, slit-lamp ophthalmoscopy, tonometry, biomicroscopy of the fundus oculi, autofluorescence and Optical Coherence Tomography (Cirrus HD-OCT version 5.1.1.6) were performed prior to surgery and repeated at each check-up.

The purely descriptive purposes of anatomical assessment led us to analyse retinal function through the examination of visual acuity rather than through other tests used to assess the visual field.

Data analysis was performed using SPSS version 13.0. Quantitative variables were expressed as averages (\pm SD) and as medians (range). Qualitative variables are expressed in frequency percentages. Appropriate parametric or non-parametric statistical tests (chi-square, Fisher's Exact, Friedman, Wilcoxon) were used to analyse results. Statistical significance was set at $p \leq 0.05$.

RESULTS

In this retrospective study the data of 23 eyes of 23 patients were analysed, 8 of whom were men (34.8%) and 15 women (65.2%). Of the 23 eyes included, 14 were right eyes (60.9%) and 9 were left eyes (39.1%).

The patients' ages ranged between 56 and 81 years, with an average (\pm SD) of 67.21 \pm 6.96 years and a median of 68.

At diagnosis the patients' far-sighted visual acuity ranged from 5 letters (1.0 logMAR) to 40 letters (0.3 logMAR) using the ETDRS, with average visual acuity (\pm SD) of 20.91 (0.68 logMAR) \pm 11.32 letters (0.88 logMAR) and a median of 23.0 letters (0.64 logMAR).

Prior to surgery the maximum and minimum diameters and height of the macular hole were calculated for each eye. Calculations were made manually and area measurements and 3D reconstruction of the macular hole were omitted. Maximum diameters were between 299.00 μ m and 1309.00 μ m with an average (\pm SD) of

770.34 $\mu\text{m} \pm 259.27 \mu\text{m}$ and a median of 760.00 μm : minimum diameters were between 50.00 μm and 623.00 μm with an average (\pm SD) of 344.26 $\mu\text{m} \pm 165.01 \mu\text{m}$ and a median of 312.00 μm ; heights were between 198.00 μm and 530.00 μm , with an average (\pm SD) of 303.54 $\mu\text{m} \pm 120.48 \mu\text{m}$ and a median of 240.50 μm .

The anatomical OCT findings showed that of the 23 holes, 21 (91.3%) had closed by one week after surgery, although a slight retrofoveal elevation remained in some cases, which settled after 30 days: 2 (8.70%) holes remained open throughout the follow-up period.

In patients with satisfactory anatomical results the RPE and the layer of photoreceptors began to regenerate in the first month, though this process was complete only after 3 months, as is shown by restoration of continuity in the RPE/photoreceptor layer complex.

The outer limiting membrane in patients with a successful surgical outcome recovered physiological continuity around 3 months after the operation.

Surface irregularities were always present on the contour of the inner retina; these improved following surgery but never completely disappeared.

Intraretinal edema, marked by the presence of optically empty intra-stromal spaces, tended to become reabsorbed already after the first week.

Seven days after surgery 10 patients showed an improvement in visual acuity, 5 patients maintained approximately stable vision compared with basal conditions and 8 patients showed a slight deterioration.

Thirty days after surgery 22 patients showed a further slight improvement in visual acuity and only 1 maintained the same status as on the 7th post-operative day. Ninety days after surgery 15 patients had further improved their visual acuity, 2 were stable at the levels of the 30th day and 6 showed a slight deterioration compared with the 30-day check-up.

At 180 days after surgery 9 patients showed further

improvement, 11 remained unchanged compared with the 90th day and 3 patients showed a deterioration in visual acuity in comparison with the previous check-up. The situation was unchanged at 360 days.

Therefore, at diagnosis the average of far-sighted visual acuity (\pm SD) was 20.91 (0.68 logMAR) \pm 11.32 letters (0.88 logMAR) and the median was 23.0 letters (0.64 logMAR); at 360 days after surgery, the average was 42.39 (0.26 logMAR) \pm 10.42 letters (0.9 logMAR) and the median was 41.00 letters (0.28 logMAR).

There were no postsurgical retinal complications after this intervention in any of the patients treated; in agreement with other reports in the literature, only a small percentage developed a secondary cataract.

DISCUSSION AND CONCLUSIONS

In the light of the above anatomical and functional results recorded at post-operative check-ups, we studied the correlations between the sample variables.

We first compared the patients' vision prior to surgery (T0) with that at 7, 30, 90, 180 and 360 days (T7, T30, T60, T180, T360) after surgery, using Friedman's and Wilcoxon's tests. The former showed that in the first interval, between T0 and T7, there was a decrease in both average and median visual acuity. In the remaining intervals (T7-T30, T30-T90, T90-T180, T180-360) visual acuity improved, particularly in the T7-T30 interval.

According to Wilcoxon's test the T0-T7, T90-T180 and T180-T360 intervals were not statistically significant ($p > 0.05$), while the other intervals were statistically significant ($p \leq 0.05$); this test also showed that the greatest significance was in the period between T7 and T30, when visual recovery was greatest.

It was then decided to analyse the correlations between the maximum and minimum diameters of the macular hole and the average thickness of the perilesional neuroepithelium, i.e. the height of the retina to the right and

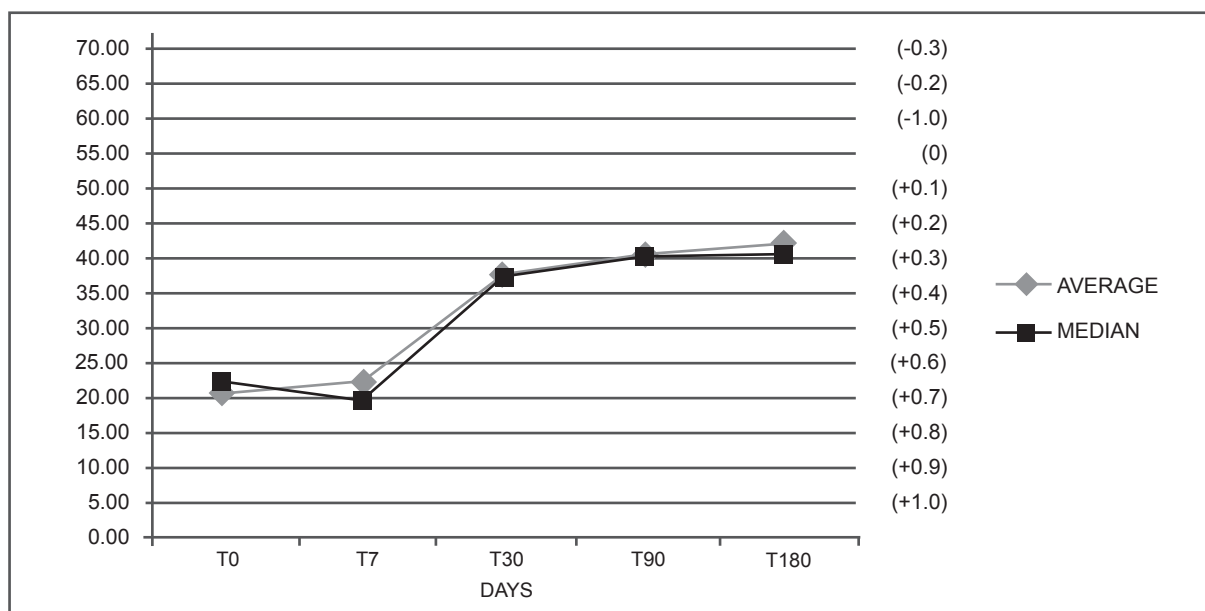


Figure 2 Trend of post-operative visual recovery. It shows the deterioration in visual acuity between T0 and T7 and the progressive improvement after T7, in particular between T7 and T30.

left of the hole, and visual acuity calculated at the three most significant moments, T0, T30 and T90.

This analysis showed that the maximum and minimum diameters have a significant effect on visual acuity prior to surgery, while the height of the retina had no statistically significant effect on visual function.

The maximum and minimum diameters also had a statistically significant influence on the recovery of vision 30 days after surgery ($p < 0.05$), though not at 90 days.

Using Pearson's correlation coefficient to estimate the strength of the correlation between the moments T0 and T30 and maximum and minimum diameters, we compared the individual statistical significances and can state that in the final analysis the influence of the maximum diameter on pre-surgery vision (T0) is greater than that of the minimum diameter, while the minimum diameter has a greater influence on visual recovery 30 days after surgery (T30) than does the maximum diameter.

We then analysed the relationship between patients' ages and visual acuity at the most significant moments: T0, T30 and T90. On the basis of our analysis age has no statistically significant influence ($p > 0.05$) on vision at T0 or T90, but does have a significant influence on the recovery of visual acuity at T30.

We found no significant correlation between gender and vision at the times analysed, nor between near-sighted vision and the diameter of the hole, nor between intraocular pressure and vision at the times analysed.

Analysis of the functional findings of post-operative visual acuity in our study shows that all patients experienced a significant improvement in vision between T7 and T90, with the greatest improvement occurring between T7 and T30. There was also a deterioration in visual acuity between T0 and T7, due to the presence of gas injected during surgery. There is clear evidence of a proportional improvement in vision up to T30, after which the patients who had experienced the greatest recovery of vision remained stable, while those whose recovery was still incomplete experienced a subsequent further improvement (Figure 2). This latter finding was also correlated with the patients' ages, revealing a sig-

nificant influence of age on the pattern of visual acuity over time; the younger patients on average attained the best possible vision at T30 and then remained essentially stable, while the best outcome for older patients was attained at T90: thus older patients required more time to recover the best possible visual acuity.

For the sake of completeness it should be noted that our study also examined the correlation between visual acuity at T0 and T30 and the maximum and minimum diameters of the macular hole of each individual patient: we found that both diameters have a significant effect on visual acuity at both T0 and T30, with a stronger correlation between the maximum diameter and pre-surgery (T0) visual acuity and between the minimum diameter and the visual outcome 30 days after surgery (T30).

The correlations between the remaining variables – near-sighted vision, endo-ocular pressure, height of the hole and gender – were not statistically significant.

In conclusion, idiopathic macular hole leads to a serious decline in visual acuity that can, nonetheless, be reversed and partially resolved by surgery: this is the reason why it is important to offer the best healthcare solutions to preserve vision and improve the quality of life and psychophysical potential of individuals.

It is thus necessary to promptly recognise and treat all retinal pathologies that can cause serious loss of vision: this should include the prevention of conditions such as hypovision, which has a considerable social and economic impact on individuals and on the healthcare system. The major psychological and psychosocial implications of hypovision should not be underestimated; better vision means a better quality of life, better mental health and better integration into domestic and social environments, as well as improved general mobility.

Conflict of interest statement

The authors have no proprietary or commercial interest in the material used in this study.

Received on 8 March 2013.

Accepted on 8 May 2013.

REFERENCES

1. Frezzotti R, Guerra R. *Oftalmologia essenziale*. 2. ed. Rozzano (MI): Casa Editrice Ambrosiana; 2006.
2. Kanski JJ. *Oftalmologia clinica*. 4. ed. Issy les Moulineaux: Elsevier Masson; 2008.
3. Risk factors for idiopathic macular holes. The Eye Disease Case-Control Study Group. *Am J Ophthalmol* 1994;118:754-61.
4. Ezra E, Wells JA, Gray RH, et al. Incidence of idiopathic full-thickness macular holes in fellow eyes. A 5-year prospective natural history study. *Ophthalmology* 1998;105:353-9.
5. Lewis ML, Cohen SM, Smiddy WE, Gass JD. Bilaterality of idiopathic macular holes. *Graefes Arch Clin Exp Ophthalmol* 1996;234:241-5.
6. Guyer DR, de Bustros S, Diener-West M, Fine SL. Observations on patients with idiopathic macular holes and cysts. *Arch Ophthalmol* 1992;110:1264-8.
7. Gaudric A, Haouchine B, Massin P, et al. Macular hole formation: new data provided by optical coherence tomography. *Arch Ophthalmol* 1999;117:744-51. DOI: 10.1001/archophth.117.6.744
8. Michalewska Z, Michalewski J, Sikorski BL, et al. A study of macular hole formation by serial spectral optical coherence tomography. *Clin Exp Ophthalmol* 2009;37:373-83. DOI: 10.1111/j.1442-9071.2009.02041.x
9. Holz FG, Spaide R. *Focus of retinal imaging*. Medical retina. Berlin: Springer-Verlag; 2010. chap 13: 141.
10. Landa A, Gentile RC, Garcia PMT, Muldoon TO and Rosen RB. External limiting membrane and visual outcome in macular hole repair: spectral domain OCT analysis. *Eye (Lond)* 2012 Jan; 26 (1): 61-9 DOI: 10.1038/eye.2011.237
11. Smiddy WE, Feuer W, Cordahi G. Internal limiting membrane peeling in macular hole surgery. *Ophthalmology* 2001;108:1471-8. DOI: 10.1016/S0161-6420(00)00645-X
12. Krohn J. Duration of face-down positioning after macular hole surgery: a comparison between 1 week and 3 days. *Acta Ophthalmol Scan* 2005;83:289-92. DOI: 10.1111/j.1600-0420.2005.00462.x
13. Tornambe PE, Poliner L, Grote K. Macular hole surgery without face-down positioning: a pilot study. *Retina* 1997;17:179-85. DOI: 10.1097/00006982-199705000-00001