

Low-cost technology for screening uterine cervical cancer^{*}

Aditya Parashari,¹ Veena Singh,² Ashok Sehgal,³ Labani Satyanarayana,⁴ Pushpa Sodhani,⁴ & Madan M. Gupta²

We report on an illuminated, low-cost (Rs 1500 (US\$ 36)) magnifying device (Magnivisualizer) for detecting precancerous lesions of the uterine cervix. A total of 403 women attending a maternal and child health care clinic who had abnormal vaginal discharge and related symptoms were referred for detailed pelvic examination and visual inspection by means of the device after the application of 5% (v/v) acetic acid. Pap smears were obtained at the same time. The results were compared with those obtained using colposcopy and/or histology. The Magnivisualizer improved the detection rate of early cancerous lesions from 60%, for unaided visual inspection, to 95%. It also permitted detection of 58% of cases of low-grade dysplasia and 83% of cases of high-grade dysplasia; none of these cases were detectable by unaided visual inspection. For low-grade dysplasia the sensitivity of detection by means of the Magnivisualizer was 57.5%, in contrast with 75.3% for cytological examination. However, the two methodologies had similar sensitivities for higher grades of lesions. The specificity of screening with the Magnivisualizer was 94.3%, while that of cytology was 99%. The cost per screening was approximately US\$ 0.55 for the Magnivisualizer and US\$ 1.10 for cytology.

Keywords: India; cervix dysplasia, diagnosis; colposcopy; diagnostic techniques, obstetrical and gynaecological, instrumentation; appropriate technology.

Voir page 966 le résumé en français. En la página 967 figura un resumen en español.

Introduction

In India, cervical cancer is the leading malignancy among women, and every year there are about 90 000 new cases. In the absence of a screening programme, most of these cases come to the attention of doctors at an advanced stage when hardly any curative management is possible. In Western countries, the incidence of and mortality attributable to cervical cancer have been brought under control by means of cytological screening programmes. It is not possible to launch nationwide screening programmes of this kind for cervical cancer in developing countries because of other compelling health problems, notably the population explosion and infectious diseases, and because of shortages of trained personnel. These limitations led to the suggestion that alternative strategies, such as visual inspection of the cervix, be employed for the control of cervical cancer (1). In a visual inspection study of approximately 44 000 women in Delhi, the following high-risk clinical signs were identified: unhealthy cervix (hypertrophied elongated cervix with abnormal discharge), bleeding ectopies, and suspicious

appearance of the cervix (2). These signs identified about 60% of cases of cervical cancer at the early clinical stage, whereas in the clinic setting fewer than 5% of cases were reported at this stage. However, visual inspection resulted in about 11% of false positives, and the detection rate of precancerous lesions was only 15–20%.

The present study was undertaken to improve the sensitivity of visual inspection and reduce the numbers of non-specific results as much as possible. For this purpose, we developed an illuminated magnifying device (Magnivisualizer) to detect precancerous and early cancerous lesions of the cervix.

Methodology

Instrument design

The Magnivisualizer (Fig. 1), developed by *A.P.*, is a portable, easily manipulated instrument that can be operated using a 12-V, 8–10 Ah dry-cell battery; it can therefore be used in rural areas where there is no mains electricity. The instrument consists of the following components:

- a light chamber consisting of a steel tube, 50 mm in length and 50 mm in diameter, with a reflector at one end and a 5-dioptre condenser lens at the other end. A 12-V, 50-W halogen bulb is situated in the centre, perforations on both sides of the light chamber to prevent overheating;
- a 2.5-dioptre magnifying lens, 100 mm in diameter, mounted at the top of the light chamber and on the edge of the condenser lens; the

^{*} From: Institute of Cytology and Preventive Oncology, Maulana Azad Medical College Campus, New Delhi 110 002, India.

¹ Research Assistant.

² Deputy Director. Correspondence should be addressed to Dr Singh.

³ Senior Deputy Director.

⁴ Assistant Director.

Ref. No. 99-0265

instrument is held by a PVC plastic grip fixed below the light chamber.

The instrument provides adequate illumination of the cervix, allowing it to be examined through the magnifying glass and for its status to be assessed. The working distance of the instrument is 10–15 cm from the outer edge of the speculum, the length of which is in the range 10–15 cm. The effective distance of the instrument from the mouth of the cervix is, therefore, approximately 25–30 cm. The distance from the eyes of the examining clinician and the lens is 40–60 cm, which is satisfactory. The cost of the instrument without a battery is US\$ 12; a rechargeable battery costs about US\$ 24 and gives approximately 2 years of use.

Subjects and methods

Women attending the maternal and child health care clinic (Sucheta Kriplani Hospital, New Delhi) and who had symptoms such as abnormal vaginal discharge, contact bleeding and irregular vaginal bleeding were referred to a gynaecologist (V.S.). All these women underwent a cytological examination and also visual inspection of the cervix by means of the Magnivisualizer after the application of 5% (v/v) acetic acid.

Statistical analysis

The results of the cytological examinations and the visual inspections were compared with diagnosis using colposcopy and/or histology. The result was taken as positive if the cervical epithelium appeared white and opaque within the transformation zone on screening with the Magnivisualizer. Cytological reporting was performed in accordance with the WHO system. Colposcopic/histological diagnosis was taken as the gold standard against which the detectability of lesions by cytological investigation and visual inspection by means of the Magnivisualizer was evaluated.

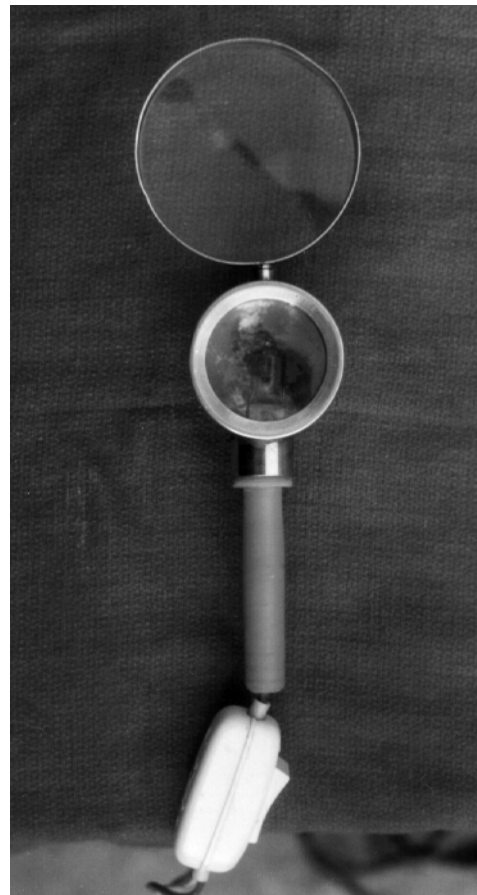
The sensitivity, specificity, number of false positives, and positive and negative predictive values were calculated using standard equations.

Results

A total of 403 women attending a maternal and child health care clinic (Sucheta Kriplani Hospital, New Delhi) were screened cytologically and examined visually by means of the Magnivisualizer. All but one of these women were also examined using a colposcope. The final diagnosis was confirmed by colposcopic directed biopsy and histological investigation. The histological studies showed that there were 73 low-grade dysplasias, 76 high-grade dysplasias, and 59 cases of carcinoma *in situ* or early invasive cancer (up to stage IIa). The results of the cytological studies and of visual inspection using the Magnivisualizer are indicated in Table 1.

Aided visual inspection using the Magnivisualizer detected 58% of the cases of low-grade dysplasia

Fig 1. Magnivisualizer consisting of lens, light chamber, grip and connecting wire



WHO 0086

demonstrated by biopsy, 83% of high-grade dysplasia cases, and 95% of cases of carcinoma *in situ* or early invasive cancer.

Cytological investigation was the more sensitive technique for detecting low-grade dysplasia (75%). However, cytological screening and the use of the Magnivisualizer were identical in terms of detecting high-grade dysplasias and carcinomas *in situ* or early invasive cancers. Of the 194 women with colposcopic and/or biopsy evidence of normal or inflammatory pathology, 183 (94.3%) had no evidence of preneoplastic/neoplastic pathology as detected by the Magnivisualizer, i.e. 94.3% specificity was achieved with this technique. Of the 194 women who showed normal/inflammatory pathology on colposcopy and/or biopsy, 192 (99%) showed the same pathology on cytological investigation, i.e. the specificity of cytological investigation was 99%. Non-specific results were given in 1% and 5.7% of cases by cytological investigation and visual inspection by means of the Magnivisualizer, respectively.

The Magnivisualizer detected 172 lesions that presented as whitish epithelium, of which 161 (93.6%) were confirmed by colposcopy or biopsy, i.e. the positive predictive value was 93.6%. Confirmation was obtained for 171 of 173 lesions detected cytologically, giving a positive predictive value of

Table 1. **Detection of lesions by Magnivisualizer and cytological investigation**

Screening method	Negative ^a <i>n</i> = 194	Positive ^b			All grades <i>n</i> = 208	Predictive value	
		Low-grade dysplasias (<i>n</i> = 73)	High-grade dysplasias (<i>n</i> = 76)	Carcinomas <i>in situ</i> or early invasive cancers (<i>n</i> = 59)		Positive predictive value	Negative predictive value
Magnivisualizer	183 94.3%	42 57.5%	63 82.9%	56 94.9%	161 77.4%	161/172 93.6%	183/230 79.6%
Cytological investigation	192 99.0%	55 75.3%	60 78.9%	56 94.9%	171 82.2%	171/173 98.8%	192/229 83.8%

^a % denote specificity.

^b % denote sensitivity.

98.8%. The negative predictive value for the Magnivisualizer was 79.6%, i.e. of the 230 women diagnosed as having no lesions by the Magnivisualizer, 183 (79.6%) had no lesions detectable by colposcopy or biopsy. However, the negative predictive value for cytological investigation was 83.8% (i.e. 192/219).

Discussion

The Magnivisualizer improved the detection rate of early cancerous lesions from 60% by unaided visual inspection (2) to 95% in the identical setting of a maternal and child health centre, and detected 58% of low-grade dysplasias and 83% of high-grade dysplasias. The detection of dysplasias was impossible with unaided visual inspection (2). Thus the use of the Magnivisualizer not only improved the sensitivity of visual inspection for invasive cancers but also led to the detection of most high-grade dysplasias. Further comparison of aided visual inspection using the Magnivisualizer with cytology also revealed that for the detection of carcinomas *in situ* or early invasive cancers and high-grade dysplasias it was as sensitive as the cytological investigation. Although the sensitivity of the Magnivisualizer is lower in the detection of low-grade dysplasias, this may not be a serious limitation as most low-grade dysplasias tend to regress even without treatment. In our experience the potential of mild dysplasia to progress is about 10%; this compares with 25% for moderate dysplasia and 50% for severe dysplasia (3).

With the cytological investigation it was found that 75% of low-grade dysplasias (*n* = 55), 79% of high-grade dysplasias (*n* = 60) and 95% of carcino-

mas *in situ* or early invasive cancers (*n* = 56), i.e. 171 of 208 dysplasias (82.2%), were detected and could therefore be treated. With the Magnivisualizer, 58% of low-grade dysplasias (*n* = 42), 83% high-grade dysplasias (*n* = 76), and 95% of carcinomas *in situ* or early invasive cancers (*n* = 56), i.e. 161 of 208 cases (77.4%), were detected. The overall sensitivities of the two techniques were therefore similar.

In India, shortcomings in infrastructure and a lack of trained personnel explain the absence of organized cytological screening programmes. Screening by visual inspection with the Magnivisualizer offers an alternative means of detecting most early cancerous and high-grade precancerous lesions that have a high potential for progression. Furthermore, this technique is comparatively inexpensive: one screening costs US\$ 0.55 with the Magnivisualizer and US\$ 1.10 if cytological investigation is performed. Costs were calculated for a hypothetical population of 100 000, taking field screening and the detection of lesions into consideration.

The simple technique of visual inspection by means of the Magnivisualizer can be undertaken even in a primary health care centre; the only additional requirement is an examination table. A biopsy can be performed at the same time, whereas with the result of the cytological investigation is not known for some time afterwards. Following the cytological detection of lesions, colposcopically directed biopsy should be performed in the interest of accurate diagnosis, whereas the use of the Magnivisualizer does not carry this requirement. Aided visual inspection is therefore likely to be of value until cytological screening becomes feasible. ■

Résumé

Technique peu coûteuse de dépistage du cancer du col utérin

Le cancer du col utérin est la principale tumeur maligne rencontrée chez les femmes indiennes. Dans les pays en

développement, il n'est pas possible de lancer des programmes nationaux de dépistage cytologique du fait

de la rareté du personnel qualifié et de l'absence des infrastructures nécessaires. La simple inspection visuelle du col est moins sensible et moins spécifique que l'examen cytologique pour détecter des cancers précoces. Le taux de détection des lésions cervicales précancéreuses était plutôt faible dans nos études antérieures. Nous avons mis au point le « Magnivisualizer », un dispositif de grossissement muni d'une source lumineuse, qui coûte 1500 roupies (US \$36), afin d'améliorer la sensibilité de l'inspection visuelle simple pour détecter des lésions précancéreuses ou des lésions cancéreuses précoces.

Cet instrument portable est facile à utiliser et fonctionne au moyen d'une pile rechargeable de 12 V. Il consiste en une chambre lumineuse avec d'un côté un réflecteur et de l'autre un condenseur, et elle est munie d'une ampoule à halogène de 50 W (12 V). Une loupe de 2,5 dioptries et de 100 mm de diamètre est fixée au sommet de la chambre lumineuse sur le bord de la lentille du condenseur. On a comparé l'inspection visuelle à l'aide du Magnivisualizer avec les résultats de la colposcopie et/ou de l'examen histologique sur un échantillon d'étude de 402 femmes. Au total, l'examen histologique a permis de diagnostiquer 73 dysplasies discrètes, 76 dysplasies graves et 59 carcinomes *in situ*

ou cancers invasifs précoces. Pour les dysplasies discrètes, la sensibilité de l'examen cytologique a été de 75,3 %, alors que celle du Magnivisualizer a été de 57,5 %. En revanche, pour les dysplasies graves et les carcinomes *in situ* ou les cancers invasifs précoces, la sensibilité a été de 94,9 % pour les deux méthodes. Le taux de faux positifs a été de 1 % pour l'examen cytologique contre 5,7 % pour le Magnivisualizer. La spécificité du dépistage a été de 94,3 % avec le Magnivisualizer et de 99 % à l'examen cytologique.

L'emploi du Magnivisualizer a sensiblement augmenté la sensibilité de l'inspection visuelle du col, non seulement pour la détection des carcinomes *in situ* ou des cancers invasifs précoces, mais également pour les lésions précancéreuses. Il a montré une sensibilité analogue à celle de l'examen cytologique pour la détection des dysplasies graves et des lésions plus graves, et a permis de réduire le nombre de faux positifs. En outre, le coût d'un dépistage au moyen du Magnivisualizer est de US \$0,55 contre US \$1,10 pour l'examen cytologique. Cette technique simple d'inspection visuelle à l'aide du Magnivisualizer peut même être utilisée dans un centre de santé primaire, le seul élément supplémentaire nécessaire étant une table d'examen.

Resumen

Tecnología de bajo costo para el cribado del cáncer cervicouterino

El cáncer cervicouterino es el tumor maligno más frecuente entre las mujeres de la India. En los países en desarrollo no es posible emprender programas de cribado citológico de ámbito nacional debido a la escasez de personal adiestrado y a la falta de la infraestructura necesaria. La simple inspección visual del cuello uterino detecta los cánceres tempranos con una menor sensibilidad y especificidad que los estudios citológicos. En nuestros estudios anteriores hallamos una tasa de detección relativamente baja de las lesiones cervicouterinas precancerosas. A raíz de ello desarrollamos el Magnivisualizador, un dispositivo de iluminación y aumento cuyo precio es de Rs 1500 (US\$ 36). Pretendíamos así mejorar la sensibilidad de la inspección visual simple en la detección de lesiones precancerosas o indicativas de cáncer temprano.

De fácil manejo, este instrumento portátil funciona con una pila recargable de 12 V. Consiste en una cámara de luz con un reflector en un lado y un condensador en el otro, equipada con una bombilla halógena de 12 V y 50 W. La cámara tiene en la parte superior, en el extremo del condensador, un cristal de aumento de 2,5 dioptrías y 100 mm de diámetro. Los resultados de la inspección visual simple realizada mediante el Magnivisualizador fueron comparados con los de la colposcopia y/o los informes histológicos en una muestra de 402 mujeres. En

total se diagnosticaron histológicamente 73 displasias leves, 76 displasias avanzadas y 59 carcinomas *in situ* o cánceres invasivos en sus primeras fases. En el caso de las displasias leves, la sensibilidad del análisis citológico fue del 75,3%, y la del Magnivisualizador, del 57,5%. En lo que atañe a las displasias graves y los carcinomas *in situ* o los cánceres invasivos tempranos, en cambio, la sensibilidad fue del 94,9% con los dos métodos. La tasa de falsos positivos fue del 1,0% en los estudios citológicos, frente al 5,7% con el Magnivisualizador. La especificidad del cribado alcanzó el 94,3% con este último, y el 99% en el análisis citológico.

El Magnivisualizador aumentó considerablemente la sensibilidad conseguida mediante la inspección visual simple, no sólo en la detección de carcinomas *in situ* o de cánceres invasivos tempranos, sino también en el caso de las lesiones precancerosas. Su sensibilidad en la detección de las displasias avanzadas y las lesiones más graves precitadas fue comparable a la del análisis citológico, y disminuyó la tasa de falsos positivos. Además, el costo del examen con Magnivisualizador fue de US\$ 0,55, mientras que el del análisis citológico fue de US\$ 1,10. La sencilla inspección visual que permite el dispositivo puede realizarse incluso en un centro de atención primaria, sin más requisito que una mesa de exploración.

References

1. **Stjernsward J et al.** Plotting a new course for cervical cancer screening in developing countries. *World Health Forum*, 1987, **8**: 42–45.
2. **Singh V, Sehgal A, Luthra UK.** Screening for cervical cancer by direct inspection. *British Medical Journal*, 1992, **304**: 534–535.
3. **Luthra UK et al.** Natural history of precancerous and cancerous lesions of the uterine cervix. *Acta Cytologica*, 1987, **11**: 226–234.