

Concurrent evaluation of visual, cytological and HPV testing as screening methods for the early detection of cervical neoplasia in Mumbai, India

Surendra S. Shastri,¹ Ketayun Dinshaw,¹ Geetanjali Amin,¹ Smriti Goswami,¹ Sharmila Patil,¹ Roshini Chinoy,¹ S. Kane,¹ Rohini Kelkar,¹ Richard Muwonge,² Cédric Mahé,² Dulhan Ajit,¹ & R. Sankaranarayanan²

Objective Naked eye visual inspection with acetic acid (VIA), magnified VIA (VIAM), visual inspection with Lugol's iodine (VILI), cytology and human papillomavirus (HPV) testing were evaluated as screening methods for the detection of high-grade squamous intraepithelial lesions (HSIL) of the uterine cervix in a cross-sectional study in Mumbai, India.

Methods Cytology, HPV testing, VIA, VIAM and VILI were carried out concurrently for 4039 women aged 30–65 years. All women were investigated with colposcopy and biopsies were taken from 939 women who had colposcopic abnormalities. The reference standard for final disease status was histology or negative colposcopy. The presence of HSIL was confirmed in 57 women (1.4%). The test characteristics for each method were calculated using standard formulae.

Results The sensitivities of cytology, HPV testing, VIA, VIAM and VILI were 57.4%, 62.0%, 59.7%, 64.9%, and 75.4%, respectively (differences were not statistically significant). The specificities were 98.6%, 93.5%, 88.4%, 86.3%, and 84.3%, respectively. Adding a visual test to cytology or HPV testing in parallel combination resulted in a substantial increase in sensitivity, with a moderate decrease in specificity. The parallel combination of VILI and HPV testing resulted in a sensitivity of 92.0% and a specificity of 79.9%.

Conclusion As a single test, cytology had the best balance of sensitivity and specificity. Visual tests are promising in low-resource settings, such as India. The use of both VIA and VILI may be considered where good quality cytology or HPV testing are not feasible. The sensitivity of cytology and HPV testing increased significantly when combined with VIA or VILI.

Keywords Cervical intraepithelial neoplasia/diagnosis/pathology; Cervix neoplasms/diagnosis/pathology; Acetic acid/diagnostic use; Colposcopy/methods; DNA probes/diagnostic use, HPV; Mass screening/methods; Physical examination/methods; Sensitivity and specificity; Cross-sectional studies; India (source: MeSH, NLM).

Mots clés Néoplasie cervicale intraépithéliale/diagnostic/anatomie pathologique/anatomie pathologique; Acide acétique/usage diagnostique; Coloscopie/méthodes; Sondes ADN HPV/usage diagnostique; Dépistage systématique/méthodes; Examen physique/méthodes; Sensibilité et spécificité (Epidémiologie); Etude section efficace; Inde (source: MeSH, INSERM).

Palabras clave Neoplasia intraepitelial del cuello uterino/diagnóstico/patología; Neoplasmas del cuello uterino/diagnóstico/patología; Acido acético/uso diagnóstico; Coloscopia/métodos; Sondas ADN HPV/uso diagnóstico; Tamizaje masivo/métodos; Examen físico/métodos; Sensibilidad y especificidad; Estudios transversales; India (fuente: DeCS, BIREME).

الكلمات المفتاحية: الأورام داخل الظهارية في عنق الرحم، تشخيص الأورام داخل الظهارية في عنق الرحم، باثولوجيا الأورام داخل الظهارية في عنق الرحم، أورام عنق الرحم، تشخيص أورام عنق الرحم، باثولوجيا أورام عنق الرحم، حمض الأسيتيك، استخدام حمض الأسيتيك في التشخيص، تنظير المهبل، طرق تنظير المهبل، مسابر الدنا، استخدام مسابر الدنا في التشخيص، الورم الحليمي البشري، المسح الجموعي، طرق المسح الجموعي، الفحص الجسدي، طرق الفحص الجسدي، الحساسية والتوعية، دراسات مستعرضة، الهند (المصدر: رؤوس الموضوعات الطبية، المكتب الإقليمي لشرق المتوسط)

Bulletin of the World Health Organization 2005;83:186-194.

Voir page 192 le résumé en français. En la página 192 figura un resumen en español.

يمكن الاطلاع على الملخص بالعربية في صفحة 193.

Introduction

An estimated 470 000 new cases of cervical cancer are diagnosed each year worldwide, and 80% of these occur in developing countries (1). A quarter of the global burden is experienced in India, where about 126 000 new cases and 71 000 deaths attributable to cervical cancer are estimated to occur each year (1, 2). Cancers of the cervix constitute 15–51% of all female cancers and rates of age-standardized incidence range from 17.2 to 55 per 100 000 women in different regions of India

(2, 3). More than 80% of cases are diagnosed at an advanced clinical stage and five-year survival is less than 40% (4, 5). In many developed countries, a decline in the incidence of and mortality caused by cervical cancer has been observed in the past 30 years as a result of screening by cytology (6, 7). Screening programmes do not exist in many developing countries, however, and in some low-resource settings where cytology programmes do exist, they have not been effective in reducing the disease burden (7).

¹ Tata Memorial Centre, Parel, Mumbai, India.

² International Agency for Research on Cancer, 150 cours Albert Thomas, 69008 Lyon, France. Correspondence should be sent to Dr Sankaranarayanan, Scientist/Medical Officer at this address (email: sankar@iarc.fr).

Ref. No. 04-012062

(Submitted: 3 February 2004 – Final revised version received: 5 April 2004 – Accepted: 6 April 2004)

There are no organized screening programmes for cervical neoplasia in India (7). Cytology-based screening programmes are difficult to organize in India owing to limited infrastructure, trained personnel, and funds. There is therefore a clear need for viable, accurate and effective alternative screening methods for the control of cervical cancer in countries with limited resources, such as India. In a collaboration between the Tata Memorial Centre (TMC) and the International Agency for Research on Cancer (IARC), Lyon, France, we conducted a cross-sectional study to concurrently evaluate the test characteristics of different approaches to screening for the early detection of high-grade squamous intraepithelial lesions (HSIL), which are precursors of cervical cancer. The approaches considered were conventional cytology, visual inspection after application of 4% acetic acid (VIA), magnified VIA with the use of a simple hand-held magnifying (4 ×) lens (VIAM), visual inspection after application of Lugol's iodine (VILI), and testing for human papillomavirus (HPV) by hybrid capture II (HC II, Digene Inc, Gaithersburg, MD, USA). This work was conducted during 2001–03, as part of a multicentre study coordinated by IARC in India and Africa (8–11). The study protocol was reviewed and approved by the scientific and ethics review committees of both the participating institutions.

Material and methods

Study design

We used a cross-sectional study design in which each screening test was carried out independently (without knowledge of the results of the alternative tests) by trained workers with a high-school education. The tests were carried out in the following order: specimen collection for cytology, specimen collection for HPV testing, VIA, VIAM, and VILI (Fig. 1). All the women screened were investigated with colposcopy by trained colposcopists, who were blinded to the results of screening tests, and biopsies were directed in women with colposcopic abnormalities suggestive of cervical neoplasia.

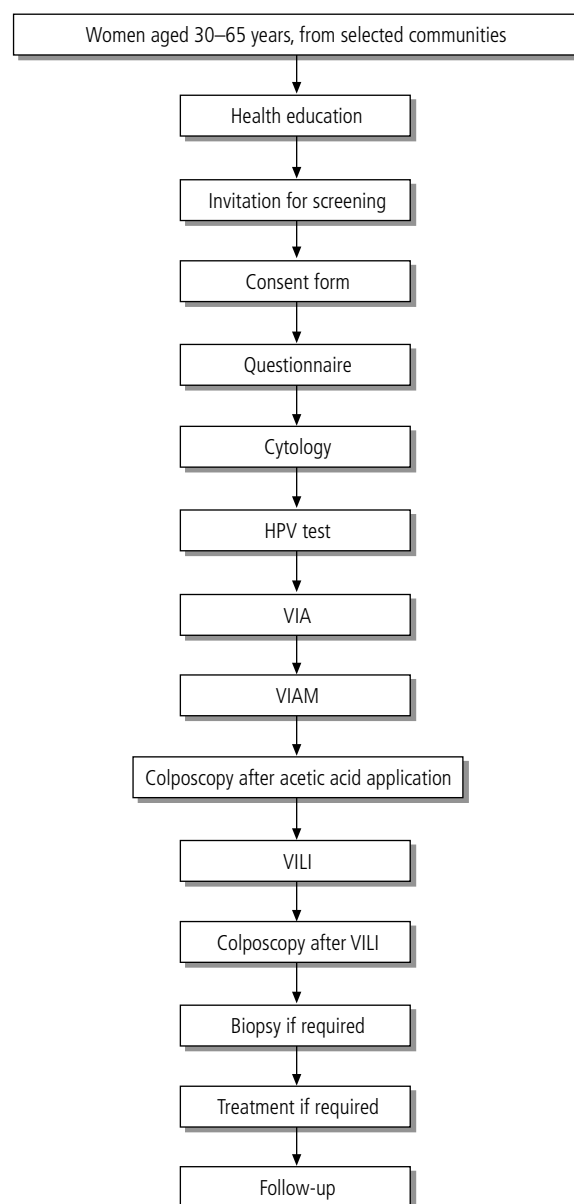
Participants

The study participants were recruited from two large slum dwellings in Mumbai. Apparently healthy, asymptomatic women aged 30–65 years with intact uterus and with no past history of cervical neoplasia were eligible to participate. Health education (including person-to-person and group methods) on the prevention of cervical cancer was introduced in the existing reproductive health-care services of the municipal health posts in the area to motivate women to participate in screening. Leaflets on cervical cancer prevention and early detection, written in the local language, were distributed. None of the participating women had been screened previously.

Training of health workers, doctors and technicians

Screening tests in the study were carried out by five female workers (high-school graduates with 12 years of schooling), who were trained in speculum examination, collection of cervical specimens for cytology and HPV testing and in performing the visual screening tests. The training, using a manual prepared by IARC (12), included lectures, discussions, review of cervical photographs, and hands-on practical experience in volunteers. Using a manual prepared by IARC (13), four doctors were trained in colposcopy, directing biopsies, cryotherapy and loop electrosurgical excision procedure (LEEP). Four technicians involved in processing cytology and biopsy specimens

Fig. 1. Screening algorithm



VIA = visual inspection with acetic acid; VIAM = visual inspection with acetic acid using low-level magnification; VILI = visual inspection with Lugol's iodine; HPV = human papillomavirus.

WHO 04.182

were reoriented. Two technicians involved in HPV testing received intensive training in testing methodology, which was standardized and validated by technicians from Digene. Three cytotechnologists and three pathologists involved in reporting were reoriented in the microscopic diagnosis of cervical intraepithelial and invasive neoplasia. Periodic refresher courses of 1–2 days in duration were conducted for all the above categories of personnel.

Data collection

A female health worker explained the details and purpose of the study to participants attending the screening clinics. A printed consent form was read out to the study participants and their signature or left thumb impression was obtained. Information

on sociodemographic and reproductive variables was then collected during an interview using a questionnaire. Screening tests and diagnostic investigations were carried out after the interview.

Screening of women

The screening clinics were conducted in 2001–03 three days per week in the municipal health posts or in mobile field clinics in the chosen areas. At the screening clinic, the participant was placed in a modified lithotomy position and the health worker examined the cervix by inserting an unlubricated bivalve vaginal speculum, with the help of a halogen focus lamp. Cervical cells were collected using a Cervex-Brush[®] (Rovers Medical Devices BV, Oss, The Netherlands); the tip of the Cervex-Brush or the spatula was placed at the cervical os and rotated gently by 360° twice to obtain a sample. A smear was prepared by spreading the specimen uniformly across a glass slide, which was immediately fixed in 95% ethyl alcohol contained in a plastic or glass jar and transported to the TMC cytology laboratory.

Next, cervical cells for HPV DNA testing were collected using the Digene cervical sampler[™] (Digene Inc, Gaithersburg, Maryland, USA). This comprises a cervical brush and standard transport medium into which the brush is inserted after collecting the cervical cells. The brush was rotated in the endocervical os and swabbed on the ectocervical epithelium, and then placed in the medium by breaking the tip of the sampler. The specimens were stored at –20 °C until further processing, and were tested at the HPV laboratory at TMC using the HC II microtitre assay (Digene Inc., Gaithersburg, MD, USA) in accordance with the manufacturers' instructions.

After the collection of cervical cells for HPV testing, the health worker applied 4% acetic acid to the cervix using a cotton swab, and excess mucus was cleared. VIA findings were recorded 1 minute after application of the acetic acid. A second health worker then examined the acetic acid-impregnated cervix with the help of a hand-held 4 × magnifying lens and reported the findings of VIAM (blinded to the results of VIA).

After VIAM, all women were examined by colposcopy by one of the four trained doctors, who were unaware of the VIA and VIAM test findings. When the colposcopic examination was completed, a third health worker (blinded to the findings on VIA, VIAM and colposcopy) applied Lugol's iodine to the cervix, and carried out VILI using naked eye examination. After VILI, colposcopy was repeated by the same doctor, and punch biopsies were obtained from areas on the cervix that were assessed by colposcopy to be abnormal. Biopsy specimens were fixed in 10% formalin and were processed and reported by the pathology laboratory of the TMC.

Definition of a positive result

Cytology results were reported according to the Bethesda system (14). Cytology was considered to be positive at the low-grade squamous intraepithelial lesion (LSIL) threshold. Cervical samples were classified as being positive for DNA from high-risk HPV types (HPV types 16, 18, 31, 33, 35, 39, 45, 51, 52, 56, 58, 59, and 68) if the relative light unit (RLU) reading obtained from the luminometer of the HC II assay equipment was equal to or greater than the mean of the positive control values supplied by the HC II kit. A positive result was recorded for specimens with a RLU:positive control ratio of 1 or greater, corresponding to 5000 or more copies of the virus. VIA and VIAM were considered to be positive if definite acetowhite lesions were

visualized close to the squamocolumnar junction, or if the entire cervix or a growth on the cervix turned acetowhite (8, 9). VILI was considered to be positive if yellow, iodine non-uptake areas were visualized close to the squamocolumnar junction, or if the entire cervix or a growth on the cervix turned yellow (8).

Reference standard and true disease

The reference standard for defining final disease status was a combination of colposcopy and biopsy. Disease status was assessed on the basis of histology if a biopsy was taken; if not, on the basis of colposcopy. Reference standard negatives included women who were assessed as normal by colposcopy, as well as those who were assessed as positive by colposcopy, but negative by histology. Since colposcopy tends to overestimate the severity of the diagnosis and to minimize any bias favouring visual screening tests, women assessed as abnormal by colposcopy and without a biopsy result (either not taken or inconclusive) were excluded from the analysis. True disease was defined as histologically confirmed HSIL. Cases of invasive cancer were excluded from the analysis in order to obtain conservative estimates of test accuracy.

Treatment

Women with HSIL were recommended to seek treatment with cryotherapy, or LEEP, or by cold knife conization. Women with LSIL were given a choice of immediate treatment or follow-up after 6 months. Cryotherapy using the double-freeze technique was performed when all the following criteria were fulfilled: fully visible lesions occupying less than 75% of the transformation zone; no extension into the endocervical canal; squamocolumnar junction fully visible; and invasive cancer excluded. Women with precursor lesions not satisfying any one of the above criteria were recommended to seek treatment with LEEP or conization. Women with invasive cancers were referred for treatment with surgery or radiotherapy.

Quality control

All health workers, technicians and doctors involved in the study were trained and reoriented at the beginning of the study and participated in periodic retraining and assessment sessions. Internal and external quality control measures were introduced in the cytology and pathology laboratories. Laboratory procedures and manuals were reviewed. On-site quality control was performed in the cytology, pathology and HPV testing laboratories at TMC.

Data management and statistical analysis

Data entry was carried out in EPIINFO (Centres for Disease Control and Prevention, Atlanta, USA). Checks for consistency and analysis were carried out in IARC using Stata 7.0 (Stata-Corp LP, Texas, USA). Sensitivity, specificity and predictive values and their 95% confidence intervals were calculated using 2 × 2 tables and standard formulae (15). The role of a second test was evaluated using data on combinations of two tests for each woman in relation to the outcome for that woman. Joint characteristics of combinations of two tests were calculated for "sequential" and "parallel" testing. Sequential testing implies screen positivity only when both the tests are positive (conversely, a negative result by either test is considered as a negative screening result). Parallel testing implies screen positivity if either test is positive (conversely, a negative result in both tests is considered as a negative screening result).

Results

A total of 4039 women aged 30–65 years participated in this study; 84% of the women were aged 30–49 years and few women were aged 60–65 years. The ages and reproductive characteristics of the participating women are given in Table 1. Most of the women had some level of education, having attended primary school (7.4%), middle school (18.8%), or high school (24.5%), and 27.3% were graduates.

All the women had colposcopy and 949 (24.8%) had directed biopsy. After exclusion of women with incomplete or inconclusive reference investigations, 4009 women were eligible for evaluation of the visual screening tests, 3749 women for evaluation of cytology and 3546 for HPV testing.

The rates of positive results for VIA, VIAM and VILI tests were 12.7%, 14.8% and 17.0%, respectively; 2.7% of cytology results were positive and 7.6% of HPV test results were positive. The distribution of test positivity rates by age group is shown in Fig. 2. Younger women had higher rates of positive results in visual tests. The reference standard established the final disease status as normal in 3818 women, while 106 had histologically confirmed LSIL, 57 had HSIL and 28 had invasive cancer. The distribution of test results and final status are given in Table 2.

The characteristics of each screening test, in terms of sensitivity, specificity, and predictive values of the positive and negative tests for detecting HSIL, are shown in Table 3. VIA, VIAM, cytology and HPV testing had similar sensitivity in detecting HSIL. Although VILI had a higher point estimate of sensitivity compared with other screening tests, the difference did not reach statistical significance. VILI had significantly lower specificity compared with VIA, VIAM, cytology and HPV testing, while the specificity of VIA and VIAM were similar. HPV testing had a higher specificity than the visual tests, but a lower specificity than cytology. The positive predictive values (PPV) of the visual tests ranged from 6.5–7.0%, while the PPV of HPV testing was 12.1%, and the highest PPV was calculated for cytology (37.8%). The negative predictive values of all tests exceeded 99.3%.

The results for a combination of two tests used in sequence and in parallel to detect HSIL are given in Table 4. The sequential test combinations resulted in a significant increase in specificity (greater than 99.0% for combinations of visual and laboratory-based tests) compared with that for the single tests, but a substantial reduction in sensitivity. Combining a visual test with cytology or HPV testing in parallel resulted in a substantial increase in sensitivity and a moderate decrease in specificity compared with those of single tests. Although the combination of VILI and HPV testing in parallel gave the highest sensitivity (92.0%), the specificity was 79.9%.

Of the 57 women diagnosed with HSIL, 15 (26.3%) had treatment with cryotherapy, 25 (43.9%) had LEEP, and 3 (5.3%) each had conization or simple hysterectomy (the remaining 14 women refused treatment). Twenty-four (22.6%) of 106 women diagnosed with LSIL accepted immediate treatment (cryotherapy, 15; LEEP, 6; simple hysterectomy, 3). Seventeen of the 28 women with invasive cancer complied with treatment.

Discussion

This study, involving asymptomatic, healthy and previously unscreened women, evaluated the comparative performance of VIA, VIAM and VILI tests provided by trained high-school

Table 1. Characteristics of the women recruited (*n* = 4039)

	No.	%
Age of women recruited (years)		
30–39	1744	43.2
40–49	1650	40.9
50–59	624	15.5
60–65	21	0.5
Premenopausal women ^a	3413	84.8
Literate women ^a	3149	78.0
Total number of pregnancies ^a		
0	103	2.6
1–2	1330	33.0
3–4	1809	44.9
≥5	791	19.6
Squamocolumnar junction visible ^a	3511	87.3

^a Percentages based on women for whom such information was available. Information was missing on menopausal status (*n* = 14), education (*n* = 2), pregnancies (*n* = 6), and squamocolumnar junction (*n* = 17).

graduates and of conventional cytology and HPV testing in detecting high-grade cervical cancer precursor lesions.

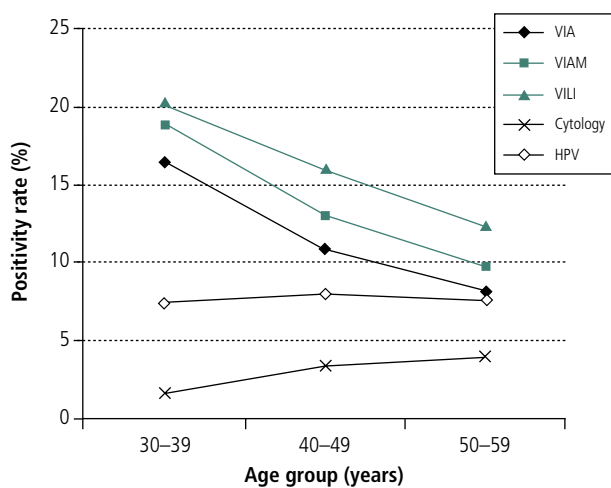
Since the reference standard was applied in all participating women, verification bias due to differential application of reference diagnostic investigations in screen-positive and screen-negative individuals was avoided to a large extent. The reference standard was provided immediately after screening, thus averting the possibility of changes in the morphology of lesions (due to regression/progression) associated with long time delays between screening and application of reference standard, interfering with assessment of test characteristics. Moreover, independence of concurrent testing and reference standard was ensured in our study.

Our results indicate that visual screening tests are promising methods for the early detection of cervical cancer. Among the visual tests assessed, VILI seems to be particularly promising, detecting three-quarters of all cases of HSIL, compared with VIA and VIAM, which detected less than two-thirds of cases. The yellow colour changes associated with a positive VILI test result were much more readily recognized by the health workers compared with the acetowhite changes associated with VIA. A major logistic advantage of the visual tests is the immediate availability of results, which allows diagnostic investigations and treatment in the same sitting as screening. However, the lower specificity of these tests implies that a large number of women will need investigations and/or treatment.

Our results with VIA are consistent with those reported in several other studies in India (8, 16), Africa (8, 17) and China (18). The sensitivity of VILI in our study was significantly lower than that observed in other studies in India and Africa (range of sensitivity, 86.7–97.0%) (8). Addition of magnification did not significantly improve the test characteristics of VIA; magnification detected three additional cases of HSIL missed by naked eye visualization in our study. Magnification did not give any improvement in the detection rate of high-grade dysplasias or cancers over the use of naked eye VIA in two studies from South Africa (19, 20), and from Kolkata, India (9).

Globally, cervical cytology is the most widely used screening test for cervical cancer, and cytology screening programmes

Fig. 2. Distribution of screen-positive rates by age group



VIA = visual inspection with acetic acid; VIAM = visual inspection with acetic acid using low-level magnification; VILI = visual inspection with Lugol's iodine; HPV = human papillomavirus testing.

WHO 04.181

in several developed countries have been associated with substantial declines in the burden of cervical cancer (6, 7). In developing countries such as Brazil, Costa Rica, Cuba, Mexico and other Latin American countries, however, such programmes have been associated with no or minimal impact on the disease burden (7). The major reasons for the lack of success, or the suboptimal performance, of cytology-based screening in less-developed countries seem to be the poor quality of several components of testing (such as adequacy of specimen collection, quality standards and variations in reporting), as well as the lack or inefficiency of programmatic components dealing with the management of screen-positive women and provision of adequate treatment and follow-up.

A wide range of sensitivities and specificities have been reported for cervical cytology. Of the eight cross-sectional studies from developing countries that permit estimation of the test characteristics of conventional cytology (10, 17, 19-24), verification bias was averted in two studies and the reported sensitivity varied from 28.9% to 76.9%, and the specificity varied between 90.2% and 98.4% (10, 17). In the cross-sectional studies with verification bias (19-24), the sensitivity of cervical cytology to detect HSIL and cancer was 13-90% and the specificity was 62-98%. In recent reviews of the accuracy of cervical cytology based on published studies in developed countries, the average sensitivity of cytology ranged from 47% to 62% and specificity ranged from 60% to 95% (25-27). On the basis of these

Table 2. Results of screening tests compared with final disease status established by the reference standard

Test result	Final disease status according to reference standard				Total
	Normal	LSIL	HSIL	Cancer	
VIA					
Negative	3433	37	23	8	3501
Positive	385	69	34	20	508
Total	3818	106	57	28	4009
VIAM					
Negative	3355	32	20	8	3415
Positive	463	74	37	20	594
Total	3818	106	57	28	4009
VILI					
Negative	3294	14	14	7	3329
Positive	524	92	43	21	680
Total	3818	106	57	28	4009
Cytology					
Negative	3524	93	23	8	3648
Positive	43	8	31	19	101
Total	3567	101	54	27	3749
HPV testing					
Negative	3190	60	19	6	3275
Positive	217	9	31	14	271
Total	3407	69	50	20	3546

VIA = visual inspection with acetic acid; VIAM = visual inspection with acetic acid using low-level magnification; VILI = visual inspection with Lugol's iodine; HPV = human papillomavirus; LSIL = low-grade squamous intraepithelial lesion; HSIL = high-grade squamous intraepithelial lesion.

reviews, the mean sensitivity and specificity for cytology was 59% and 75%, respectively. Among the single tests in our study, cervical cytology demonstrated the best balance of sensitivity, specificity and predictive values. A combination of inputs in training, and quality control seems to be responsible for the satisfactory performance of cytology in our study. An optimum performance of cytology cannot be ensured unless these requirements are met.

The causal association of persistent infection with certain HPV types and cervical neoplasia is well established (28, 29). This knowledge has encouraged the evaluation of HPV testing in the early detection of cervical neoplasia. The sensitivity of HPV testing by HC II was moderately high in our study, and was similar to that reported for women in Kolkata, India (11), HIV-negative women in Zimbabwe (30, 31), in self-sampling

Table 3. Accuracy of screening tests for the detection of high-grade squamous intraepithelial lesions (HSIL)

Test	Sensitivity (95% CI)	Specificity (95% CI)	Positive predictive value	Negative predictive value
VIA	59.7 (45.8-72.4)	88.4 (87.4-89.4)	7.0	99.3
VIAM	64.9 (51.1-77.1)	86.3 (85.2-87.4)	6.5	99.4
VILI	75.4 (62.2-85.9)	84.3 (83.1-85.4)	6.5	99.6
Cytology	57.4 (43.2-70.8)	98.6 (98.2-99.0)	37.8	99.4
HPV testing	62.0 (47.2-75.4)	93.5 (92.6-94.3)	12.1	99.4

VIA = visual inspection with acetic acid; VIAM = visual inspection with acetic acid using low-level magnification; VILI = visual inspection with Lugol's iodine; HPV = human papillomavirus; CI = confidence interval.

Table 4. Accuracy of combined screening tests for the detection of high-grade squamous intraepithelial lesions (HSIL)

Test combination	Positivity ^a	Sensitivity (95% CI)	Specificity (95% CI)	Positive predictive value	Negative predictive value
VIA and VILI	Both results positive	56.1 (42.4–69.3)	90.4 (89.4–91.3)	7.8	99.3
	Either result positive	79.0 (66.1–88.6)	82.4 (81.1–83.6)	6.1	99.6
VIA and cytology	Both results positive	31.5 (19.5–45.6)	99.7 (99.4–99.8)	58.6	99.0
	Either result positive	83.3 (70.7–92.1)	87.4 (86.2–88.4)	8.8	99.7
VIA and HPV	Both results positive	34.0 (21.2–48.8)	99.1 (98.7–99.4)	34.7	99.1
	Either result positive	90.0 (78.2–96.7)	83.3 (82.0–84.5)	7.2	99.8
VILI and cytology	Both results positive	42.6 (29.2–56.8)	99.6 (99.4–99.8)	62.2	99.2
	Either result positive	88.9 (77.4–95.8)	83.2 (81.9–84.4)	7.2	99.8
VILI and HPV	Both results positive	48.0 (33.7–62.6)	98.9 (98.5–99.2)	38.7	99.3
	Either result positive	92.0 (80.8–97.8)	79.9 (78.5–81.2)	6.2	99.9
Cytology and HPV	Both results positive	46.8 (32.1–61.9)	99.4 (99.1–99.7)	53.7	99.2
	Either result positive	72.3 (57.4–84.4)	92.8 (91.8–93.6)	12.7	99.6

^a Positivity was defined as follows: sequential testing, both tests gave positive results; parallel testing, either test gave a positive result.

VIA = visual inspection with acetic acid; VIAM = visual inspection with acetic acid using low-level magnification; VILI = visual inspection with Lugol's iodine; HPV = human papillomavirus testing; CI = confidence interval.

studies (24, 32–34), and in studies in which a statistical adjustment was made for verification bias (35, 36). Sensitivity exceeded 90% in studies in which no adjustment was made for verification bias (37–41). However, HPV testing is expensive and requires a sophisticated infrastructure for collection, storage and testing of specimens to ensure optimum performance; this may not be feasible in many low-resource settings.

Although our study establishes the feasibility of using trained, non-medical and non-nursing personnel to provide visual tests and collect cervical specimens for cytology and HPV testing, the accuracy of these tests in studies using nursing/medical/paramedical personnel is significantly higher (8–11, 18, 24). We believe that non-medical and non-nursing personnel would need more experience to acquire a proficiency approaching that of health workers with nursing/clinical and other paramedical educational background. In Kolkata, India, in two successive studies involving the same non-nursing workers (8, 11), the sensitivity of VIA improved from 56.1% to 71.4%, with a slight improvement in specificity (from 82.2% to 89.5%); similarly, the sensitivity for HPV testing improved from 45.7% to 69.8% in these two successive studies. This improvement was partly attributed to the improved skills of these workers as they gained experience in providing the visual test and improved proficiency in the collection of specimens.

We wished to evaluate whether the performance of single tests could be improved by adding a second test, assessed by testing in sequence and in parallel, and we have provided accuracy estimates for various combinations of VIA, VILI, cytology and HPV testing. Our results suggest that the performance of cytology and HPV testing in detecting HSIL can be improved by adding a visual test in parallel, in particular, a combination of VILI and HPV. A parallel combination of VIA and HPV resulted in the highest sensitivity, 93.2%, but a specificity of only 43.3% in Zimbabwe (31). If one assumes that detecting true positive cases is a priority for screening programmes, our

results suggest that parallel testing with a visual and laboratory-based test may be worth considering. It remains to be established whether the additional costs incurred by using a second test can be compensated by increasing the interval between screening rounds. In settings where only infrequent screening (e.g. once per lifetime, or once per 10 years) is possible and it is not feasible to provide good quality cytology or HPV testing, the use of a parallel combination of both VIA and VILI (Table 4) should be considered.

In conclusion, as a single test, cytology was associated with the best balance of sensitivity, specificity and predictive values, on the basis of our findings. Visual tests constitute a promising approach in low-resource settings and evidence from on-going studies on their ability to reduce incidence of and mortality from cervical cancer is crucial (2, 42). Parallel testing with both acetic acid and Lugol's iodine may be considered for early detection of cervical neoplasia in settings where provision of good quality cytology or HPV testing is not feasible in view of technical, personnel, infrastructure and financial constraints. The sensitivity of cytology and HPV testing increased significantly by adding a visual test, such as VIA or VILI, and the cost implications of these approaches remain to be established. ■

Acknowledgements

The authors gratefully acknowledge the generous support of The Bill & Melinda Gates Foundation to this study through the Alliance for Cervical Cancer Prevention (ACCP). We thank Dr John Sellors, Program for Appropriate Technology in Health (PATH), Seattle, USA and Dr Ramani Wesley, Regional Cancer Centre, Trivandrum, India, for training our workers in VIA, VILI, colposcopy, cryotherapy and LEEP. Our thanks are due to Ms Sophie Sibert-Dardenne and Mrs Evelyn Bayle for help in preparing the manuscript.

Conflicts of interest: none declared.

Résumé

Évaluation en parallèle de l'inspection visuelle, de l'examen cytologique et du test HPV comme méthodes de dépistage pour la détection précoce des néoplasies cervicales à Mumbai, Inde

Objectif Dans le cadre d'une étude transversale menée à Mumbai, Inde, les auteurs ont évalué l'inspection visuelle à l'œil nu après application d'acide acétique (VIA), la VIA avec grossissement (VIAM), l'inspection visuelle au soluté de Lugol (iodure de potassium, VILI), l'examen cytologique et le test de dépistage de l'infection à papillomavirus (test HPV), comme méthodes de dépistage des lésions malpighiennes intra-épithéliales de haut grade (HSIL) du col utérin.

Méthodes On a réalisé en parallèle un examen cytologique, un test HPV, une VIA, une VIAM et une VILI sur 4039 femmes âgées de 30 à 65 ans. Toutes ces femmes ont subi une colposcopie et on a effectué une biopsie chez 939 d'entre elles, qui présentaient des anomalies colposcopiques. La référence servant à définir l'état pathologique final était l'examen histologique ou la colposcopie négative. La présence d'une HSIL a été confirmée chez 57 femmes (1,4 %). On a calculé les caractéristiques de chacune des méthodes à l'aide de formules standards.

Résultats Les sensibilités de l'examen cytologique, du test HPV, de la VIA, de la VIAM et de la VILI ont été évaluées respectivement

à 57,4 %, 62,0 %, 59,7 %, 64,9 % et 75,4 % (les différences n'étaient pas statistiquement significatives). Les spécificités ont été évaluées respectivement à 98,6 %, 93,5 %, 88,4 %, 86,3 % et 84,3 %. Le fait de combiner une inspection visuelle à l'examen cytologique ou au test HPV a permis d'accroître substantiellement la sensibilité de l'examen, avec une baisse modérée de la spécificité. L'association en parallèle de la VILI et du test HPV a permis d'atteindre une sensibilité de 92,0 % et une spécificité de 79,9 %.

Conclusion Si l'on n'utilise qu'un seul test, c'est l'examen cytologique qui présente le meilleur équilibre entre sensibilité et spécificité. Les examens visuels constituent une solution prometteuse dans les pays à faibles ressources comme l'Inde. On peut envisager de combiner la VIA et la VILI lorsqu'un examen cytologique ou un test HPV de bonne qualité ne peut être pratiqué. La sensibilité de l'examen cytologique et du test HPV augmente notablement lorsqu'on associe ces examens à la VIA ou à la VILI.

Resumen

Inspección visual, citología y pruebas del VPH simultáneas como métodos de cribado para la detección precoz de la neoplasia cervicouterina en Mumbai (India)

Objetivo En un estudio transversal llevado a cabo en Mumbai (India) se evaluaron la inspección visual simple con ácido acético (IVA), la IVA amplificada (IVAA), la inspección visual con yodo de Lugol (IVYL), el examen citológico y las pruebas del VPH (papilomavirus humano) como métodos de cribado de la neoplasia intraepitelial escamosa de alto grado (NIEA) del cuello uterino.

Métodos Un total de 4039 mujeres de 30–65 años fueron sometidas a las siguientes pruebas realizadas en paralelo: examen citológico, pruebas del VPH, IVA, IVAA e IVYL. Todas las mujeres fueron exploradas mediante colposcopia, efectuándose biopsias en los 939 casos en que se detectaron anomalías colposcópicas. El criterio adoptado para determinar el estadio final de la enfermedad fue la histología o una colposcopia negativa. Se confirmó la existencia de NIEA en 57 mujeres (1,4%). Las características de cada método se calcularon mediante fórmulas estándar.

Resultados Las sensibilidades de la citología, las pruebas del VPH, la IVA, la IVAA y la IVYL fueron del 57,4%, 62,0%, 59,7%,

64,9% y 75,4%, respectivamente (diferencias sin significación estadística). Las especificidades fueron del 98,6%, 93,5%, 88,4%, 86,3% y 84,3%, respectivamente. La combinación paralela de una prueba visual y la citología o la prueba del VPH aumentaba sustancialmente la sensibilidad, con una disminución moderada de la especificidad. La combinación paralela de la IVYL y la prueba del VPH obtuvo una sensibilidad del 92,0% y una especificidad del 79,9%.

Conclusión Como prueba única, el examen citológico supone el mejor compromiso entre sensibilidad y especificidad. Las pruebas visuales son prometedoras en los entornos con pocos recursos, como la India. Cabe plantearse la posibilidad de usar la IVA y la IVYL en los casos en que no sea factible realizar un análisis citológico o unas pruebas del VPH de buena calidad. La sensibilidad de la citología y la prueba del VPH aumentó significativamente cuando se combinó con la IVA o la IVYL.

ملخص

التقييم الراهن للاختبار البصري والسييتولوجي وتحري الورم الحليمي البشري كطرق لتحري الكشف الباكر لأورام عنق الرحم في بومباي، الهند

الهدف: تم تقييم الفحص البصري بالعين المجردة مع استخدام حمض الأسيتيك، ثم الفحص البصري مع التكبير ثم الفحص البصري مع استخدام محلول لوغول اليودي ثم الفحص السييتولوجي ثم اختبار تحري الورم الحليمي البشري باعتبارها طرقاً للكشف عن الأورام الحشوية داخل الظهارية الرفيعة الدرجة في عنق الرحم وذلك في دراسة مستعرضة في بومباي في الهند.

الطريقة: لقد تم إجراء كل من الفحص البصري بالعين المجردة ثم الفحص البصري مع استخدام حمض الأسيتيك ثم الفحص البصري مع التكبير ثم الفحص البصري مع استخدام محلول لوغول اليودي ثم اختبار تحري الورم الحليمي البشري لدى 4039 من النسوة اللاتي تتراوح أعمارهن بين 30 و 65 عاماً. وقد أجري لجميع هؤلاء النسوة الفحص بالتنظير المهبل وأخذت عينات من 939 منهن ممن كان لديهن شذوذات بالتنظير المهبل. وقد كان المعيار المرجعي للوضع النهائي للمرض هو سلبية الفحص الهستولوجي أو سلبية التنظير المهبل. لقد تم التأكد من وجود آفات حشوية ظهارية رفيعة الدرجة لدى 57 امرأة (1.4%)، وقد حسبت خصائص كل فحص في كل طريقة باستخدام معادلات حساسية قياسية.

النتائج: لقد كانت حساسية الفحص السييتولوجي 57.4% وحساسية اختبار تحري الورم الحليمي البشري 62.0% وحساسية الفحص البصري مع استخدام حمض الأسيتيك 59.7% وحساسية الفحص البصري مع استخدام التكبير وحمض الأسيتيك معاً 64.9% وحساسية الفحص البصري مع

استخدام محلول لوغول اليودي 75.4% وهكذا فإن الفروقات لم تكن ذات أهمية إحصائية، أما بالنسبة لنوعية هذه الفحوص فقد كانت بالنسبة للفحص السييتولوجي 98.6% وبالنسبة لاختبار تحري الورم الحليمي البشري 93.5% وبالنسبة للفحص البصري مع استخدام حمض الأسيتيك 88.4% وبالنسبة للفحص البصري مع استخدام التكبير وحمض الأسيتيك معاً 86.3% وبالنسبة للفحص البصري مع استخدام محلول لوغول اليودي 84.4% وقد أدى إضافة الفحص البصري إلى الفحص السييتولوجي أو إلى اختبار تحري الورم الحليمي البشري إلى ازدياد هام في الحساسية عند الجمع المتوازي بينهما، مع نقص طفيف في النوعية. إن الجمع المتوازي لكل من الفحص البصري مع استخدام محلول لوغول اليودي واختبار تحري الورم الحليمي البشري أدى إلى حساسية مقدارها 92.0% ونوعية مقدارها 79.9%.

الاستنتاج: إذا أخذنا فحصاً وحيداً فإن الفحص السييتولوجي يحقق أفضل توازن بين الحساسية والنوعية. أما الفحوص البصرية فهي ذات فائدة مرجوة في المواقع ذات الموارد المنخفضة مثل الهند. إن الجمع بين كل من الفحص البصري مع استخدام حمض الأسيتيك الفحص البصري مع استخدام محلول لوغول اليودي قد يؤخذ بالاعتبار عند عدم توافر فحوص سييتولوجية رفيعة الجودة وعند عدم توافر اختبار تحري الورم الحليمي البشري. وتزداد حساسية الفحص السييتولوجي واختبار تحري الورم الحليمي البشري زيادة ملحوظة عند جمعهما مع كل من الفحص البصري باستخدام حمض الأسيتيك والفحص البصري مع استخدام محلول لوغول اليودي.

References

1. Ferlay J, Bray F, Pisani P, Parkin DM. *GLOBOCAN 2000: Cancer incidence, mortality and prevalence worldwide*. Version 1.0., IARC CancerBase No.5, Lyon: IARC Press; 2001.
2. Sankaranarayanan R, Nene BM, Dinshaw K, Rajkumar R, Shastri S, Wesley R, et al. Early detection of cervical cancer with visual inspection methods: a summary of completed and on-going studies in India. *Salud Publica de Mexico* 2003; 45 Supp.12:5274-82.
3. Nandakumar A. *National Cancer Registry Programme, Indian Council of Medical Research, consolidated report of the population based cancer registries*. New Delhi, India; 1990-1996. p. 60.
4. Dinshaw KA, Rao DN, Ganesh B. *Tata Memorial Hospital Cancer Registry annual report*, Mumbai, India; 1999. p. 52.
5. Sankaranarayanan R, Black RB, Parkin DM, editors. *Cancer survival in developing countries*. Lyon: IARC Press; 1998 (IARC Scientific Publications No. 145).
6. IARC Working Group on Cervical Cancer Screening. Summary chapter. In: Hakama M, Miller AB, Day NE, editors. *Screening for cancer of the uterine cervix*. Lyon: IARC Press; 1986. p. 133-42 (IARC Scientific Publications No. 76).
7. Sankaranarayanan R, Budukh A, Rajkumar R. Effective screening programmes for cervical cancer in low- and middle-income developing countries. *Bulletin of the World Health Organization* 2001;79:954-62.
8. Sankaranarayanan R, Basu P, Wesley R, Mahé C, Keita N, Gombe C, et al. Accuracy of visual screening for cervical neoplasia: Results from an IARC multicentre study in India and Africa. *International Journal of Cancer* 2004;110:907-13.
9. Sankaranarayanan R, Shastri S, Basu P, Mahé C, Mandal R, Amin G, et al. The role of low-level magnification in visual inspection with acetic acid for the early detection of cervical neoplasia. *Cancer Detection and Prevention* 2004;28:245-51.
10. Sankaranarayanan R, Thara S, Sharma A, Roy C, Shastri S, Mahé C, et al. Accuracy of conventional cytology: results from a multicentre screening study in India. *Journal of Medical Screening* 2004;11:77-84.
11. Sankaranarayanan R, Chatterji R, Shastri S, Wesley R, Mahé C, Muwonge R, et al. Accuracy of human papillomavirus testing in primary screening of cervical neoplasia: results from a multicentre study in India. *International Journal of Cancer* 2004;112:341-7.
12. Sankaranarayanan R, Wesley R. *A practical manual on visual screening for cervical neoplasia*. Lyon: IARC Press; 2003 (IARC Technical Publication No. 41).
13. Sellors J, Sankaranarayanan R. *Colposcopy and treatment of cervical intraepithelial neoplasia: A beginners' manual*. Lyon: IARC Press; 2003.
14. Kurman RJ, Malkasian GD Jr, Sedis A, Solomon D. From Papanicolaou to Bethesda: the rationale for a new cervical cytologic classification. *Obstetrics and Gynecology* 1991;77:779-82.
15. Santos Silva I, editor. *Cancer epidemiology, principles and methods*. Lyon: IARC Press; 1999.
16. Basu P, Sankaranarayanan R, Mandal R, Roy C, Das P, Choudhury D, et al. The Calcutta Cervical Cancer Early Detection Group. Visual inspection with acetic acid and cytology in the early detection of cervical neoplasia in Kolkata, India. *International Journal of Gynecological Cancer* 2003;13:626-32.
17. University of Zimbabwe/JHPIEGO Cervical Cancer Project. Visual inspection with acetic acid for cervical cancer screening: test qualities in a primary-care setting. *Lancet* 1999;353:869-73.
18. Belinson JL, Pretorius RG, Zhang WH, Wu LY, Qiao YL, Elson P. Cervical cancer screening by simple visual inspection after acetic acid. *Obstetrics and Gynecology* 2001;98:441-4.
19. Denny L, Kuhn L, Pollack A, Wainwright H, Wright T. Evaluation of alternative methods of cervical cancer screening in resource poor settings. *Cancer* 2000;89:826-33.
20. Denny L, Kuhn L, Pollack A, Wright TC Jr. Direct visual inspection for cervical cancer screening: an analysis of factors influencing test performance. *Cancer* 2002;94:1699-707.
21. Londhe M, George SS, Seshadri L. Detection of CIN by naked eye visualization after application of acetic acid. *Indian Journal of Cancer* 1997;34:88-91.

22. Sankaranarayanan R, Shyamalakumari B, Wesley R, Sreedevi Amma N, Parkin DM, Nair MK. Visual inspection with acetic acid in the early detection of cervical cancer and precancers. *International Journal of Cancer* 1999;80:161-3.
23. Sankaranarayanan R, Wesley R, Somanathan T, Dhakad N, Shyamalakumary B, Aroma NS, et al. Visual inspection of the uterine cervix after application of acetic acid in the detection of cervical carcinoma and its precursors. *Cancer* 1998; 83:2150-6.
24. Salmeron J, Lazcano-Ponce E, Lorincz A, Hernandez M, Hernandez P, Leyva A, et al. Comparison of HPV-based assays with Papanicolaou smears for cervical cancer screening in Morelos State, Mexico. *Cancer Causes and Control* 2003;14:505-12
25. Fahey MT, Irwig L, Macaskill P. Meta-analysis of Pap test accuracy. *American Journal of Epidemiology* 1995;141:680-9.
26. Mitchell MF, Schottenfeld D, Tortolera-Luna G, Cantor SB, Richards-Kortum R. Colposcopy for the diagnosis of squamous extraepithelial lesions: a meta-analysis. *Obstetrics and Gynecology* 1998;91:626-31.
27. Nanda K, McCrory DC, Myers ER, Bastian LA, Hasselblad V, Hickey JD, et al. Accuracy of the Papanicolaou test in screening for and follow-up of cervical cytologic abnormalities: A systematic review. *Annals of Internal Medicine* 2000;132:810-9.
28. International Agency for Research on Cancer Working Group on the Evaluation of Carcinogenic Risks to Humans. *Human Papillomaviruses*. Lyon: IARC Press; 1995 (IARC monographs on the Evaluation of Carcinogenic Risks to Humans. Vol. 64).
29. Bosch FX, Lorincz A, Munoz N, Meijer CJ, Shah KV. The causal relation between human papillomavirus and cervical cancer. *Journal of Clinical Pathology* 2002;55:244-65.
30. Womack SD, Chirenje ZM, Blumenthal PD, Gaffikin L, McGrath JA, Chipato T, et al. Evaluation of a human papillomavirus assay in cervical screening in Zimbabwe. *BJOC: an international journal of obstetrics and gynaecology* 2000;107:33-8.
31. Blumenthal PD, Gaffikin L, Chirenje ZM, McGrath J, Womack S, Shah K. Adjunctive testing for cervical cancer in low resource settings with visual inspection, HPV, and the Pap smear. *International Journal of Gynaecology and Obstetrics* 2001;72:47-53.
32. Sellors JW, Lorincz AT, Mahony JB, Mielzynska I, Lytwyn A, Roth P, et al. Comparison of self-collected vaginal, vulvar and urine samples with physician-collected cervical samples for human papillomavirus testing to detect high-grade squamous intraepithelial lesions. *Canadian Medical Association Journal* 2000;163:513-28.
33. Garcia F, Barker B, Santos C, Brown EM, Nuno T, Giuliano A, et al. Cross-sectional study of patient- and physician-collected cervical cytology and human papillomavirus. *Obstetrics and Gynecology* 2003;102:266-72
34. Wright TC Jr, Denny L, Kuhn L, Pollack A, Lorinez A. HPV DNA testing of self-collected vaginal samples compared with cytologic screening to detect cervical cancer. *JAMA* 2000;283:81-6.
35. Ratnam S, Franco EL, Ferenczy A. Human papillomavirus testing for primary screening of cervical cancer precursors. *Cancer Epidemiology Biomarkers and Prevention* 2000;9:945-51.
36. Kulasingham SL, Hughes JP, Kiviat NB, Mao C, Weiss NS, Kuypers JM, et al. Evaluation of human papillomavirus testing in primary screening for cervical abnormalities: comparison of sensitivity, specificity, and frequency of referral. *JAMA* 2002;288:1749-57.
37. Cuzick J, Beverley E, Ho L, Terry G, Sapper H, Mielzynska I, et al. HPV testing in primary screening of older women. *British Journal of Cancer* 1999;81:554-8.
38. Clavel C, Masure M, Bory JP, Putaud I, Mangeonjean C, Lorenzato M, et al. Hybrid capture II-based human papillomavirus detection, a sensitive test to detect in routine high-grade cervical lesions: a preliminary study on 1518 women. *British Journal of Cancer* 1999;80:1306-11.
39. Clavel C, Masure M, Bory JP, Putaud I, Mangeonjean C, Lorenzato M, et al. Human papillomavirus testing in primary screening for the detection of high-grade cervical lesions: a study of 7932 women. *British Journal of Cancer* 2001;84:1616-23.
40. Petry K-U, Menton S, Menton M, van Loenen-Frosch F, de Carvalho Gomes H, Holz B, et al. Inclusion of HPV testing in routine cervical cancer screening for women above 29 years in Germany: results for 8466 patients. *British Journal of Cancer* 2003;88:1570-7.
41. Kuhn L, Denny L, Pollack A, Lorincz A, Richart RM, Wright TC. Human papillomavirus testing for cervical cancer screening in low-resource settings. *Journal of the National Cancer Institute* 2000;92:818-25.
42. Sankaranarayanan R, Rajkumar R, Theresa R, Esmay PO, Mahe C, Bagyalakshmi KR, et al. Initial results from a randomized trial of cervical visual screening in India. *International Journal of Cancer* 2004;109:461-7.