

BRIEF REPORT

LETHAL ENCEPHALITIS DUE TO FREE-LIVING AMOEBAE IN THREE MEMBERS OF A FAMILY, IN TUMBES, PERU

María Edith Solís-Castro ^{1,2,a}¹ Centro Nacional de Epidemiología, Prevención y Control de Enfermedades, Lima, Perú.² Programa de Especialización en Epidemiología de Campo, Universidad Nacional Mayor de San Marcos, Lima, Perú.^a Physician, Doctor of Health Sciences

ABSTRACT

Free-living amoebas (FLA) are protozoan parasites that occasionally cause disease in humans after contact with contaminated water or soil. We describe a series of three cases of encephalitis in a family group with a fatal outcome that occurred in the Tumbes region between December 2019 and February 2020. *Acanthamoeba* sp. was identified in the cerebrospinal fluid sample from case 1. All three cases had a history of entering a swimming pool months before the disease. In the Tumbes region there is no previous record of encephalitis due to FLA and its occurrence in a family cluster has never been reported before.

Keywords: Encephalitis; Central Nervous System Protozoal Infections; *Acanthamoeba*; Amebiasis. (Source: MeSH NLM)

INTRODUCTION

Free-living amoebae (FLA) are protists distributed in different habitats, occasionally acting as opportunistic parasites causing disease in humans. The FLA recognized as human pathogens are *Naegleria fowleri*, several species of *Acanthamoeba* and *Balamuthia mandrillaris* ⁽¹⁾. Two clinical syndromes are distinguished: primary amoebic meningoencephalitis (PAM), and granulomatous amebic encephalitis (GAE) ^(2,3).

Pathogenic strains of *Acanthamoeba* cause GAE, skin infections in immunocompromised individuals, and amoebic keratitis in immunocompetent individuals ^(4,5). These amoebae enter through nasopharyngeal mucosa, skin lesions, eyes in contact lens users or corneal trauma ⁽⁶⁾. Disease manifests with weeks or months of headache, visual disturbances, behavioral abnormalities, and focal neurological deficits. The incubation period is generally unknown, as it is often difficult to determine when exposure occurred ⁽⁷⁾.

N. fowleri causes PAM with mortality of almost 95% ⁽⁸⁾ generally after swimming, recreational aquatic activities or contact with infected water ⁽⁹⁾. *B. mandrillaris* causes GAE, usually fatal. The likely portal of entry is the nasal cavity or skin ⁽¹⁰⁾.

FLA have a worldwide distribution. In South America, cases of *Acanthamoeba* and *B. mandrillaris* have been described in immunocompromised patients. In Peru, since 1970, cases of GAE have been found in the coast (Piura, Lima, and Ica), related to *B. mandrillaris* ⁽¹⁰⁾. In Tumbes, there are no previous report of cases of FLA disease, and no reports of an outbreak of FLA encephalitis in a family cluster have been found in the literature.

This study presents a series of three cases of lethal encephalitis by *Acanthamoeba* in a nuclear family in Tumbes, Peru.

Cite as: Solís-Castro ME. [Lethal encephalitis due to free-living amoebae in three members of a family, in Tumbes, Peru]. Rev Peru Med Exp Salud Publica 2021;38(2):291-5. doi: <https://doi.org/10.17843/rpmesp.2021.382.6754>.

Correspondence:

María Edith Solís Castro;
medithsol@gmail.com

Received: 11/15/2020

Approved: 02/24/2021

Online: 05/19/2021

THE STUDY

Tumbes is located on the northern coast of Peru (3°34'0 "S, 80°26'29 "W) and has a semitropical climate with an average temperature of 25.3 °C. However, when El Niño phenomenon occurs, temperatures reach 40 °C with heavy rainfall and flooding. The socioenvironmental and sanitary conditions of the region favor the presence of tropical diseases.

The National Center for Epidemiology, Disease Control and Prevention (CDC) was notified of a case of febrile syndrome with neurological manifestations in a one-year-old boy, with history of a father and brother who had died in the previous months with diagnosis of encephalitis.

The information was obtained from medical records; the relatives of the deceased were interviewed to look for history of exposure. Diagnoses compatible with encephalitis, febrile syndrome, and convulsions were sought in the outpatient, emergency, and hospitalization databases of local health facilities and hospitals. The health facility in the jurisdiction conducted a community case search. The case definition used was a person who in the last six months had presented headache and neurological manifestations characterized by altered consciousness, with or without fever, with a history of previous exposure to stagnant water, swimming pools or ponds in Tumbes.

The data for this investigation were obtained from an outbreak investigation conducted by the CDC of Peru. A timeline was constructed for the description and temporality of the cases (Figure 1).

FINDINGS

Description of the cases

During 2019 and 2020, three cases of FLA lethal encephalitis occurred within a family in Tumbes, Peru. The nuclear family was father, mother, and two sons aged six and one year.

The first case was a boy aged one year and seven months with history of prematurity (28 weeks, weight 1,800 g); on January 28, 2020, he had fever (40 °C), muscle weakness of upper and lower limbs, cough, and generalized tonic-clonic convulsions. He was treated at a local hospital and had the following laboratory results: hemoglobin, 9.4 g/dL; negative serological test for dengue, leptospirosis, and blood parasites (thick blood smear). Due to information about his

KEY MESSAGES

Motivation for the study: Free-living amoebae are protozoan parasites that occasionally cause disease in humans.

Main findings: The characteristics of an outbreak of encephalitis due to free-living amoebae in three members of a family in Tumbes with fatal outcome.

Implications: Permanent surveillance of water quality by the health authorities and the monitoring of public swimming pools are recommended.

relatives, who died in the previous weeks with a diagnosis of encephalitis, the patient was referred to more complex hospitals in Piura and Lambayeque, where he received anticonvulsants, antibiotic therapy for suspected bacterial meningoencephalitis, and abolition of osteotendinous reflexes. The result of the computed axial tomography showed cerebral edema; lumbar puncture was not performed due to lack of reagents. The clinical picture did not improve, and the patient died seven days after the onset of symptoms. Informed consent was obtained to obtain a postmortem cerebrospinal fluid (CSF) sample, which was sent to the Instituto Nacional de Salud (INS) where *Acanthamoeba* sp. trophozoites were reported.

The second case was a 28-year-old adult, father of the other cases. He had a history of repeated urinary tract infections (UTI) which were treated with self-medication. In October 2019, he experienced generalized weakness, myalgias, diffuse headache, and forgetfulness episodes. The patient did not seek medical attention because his son, the third case in our series, was hospitalized. On January 18, 2020, he attended the local hospital with unquantified fever, severe headache, drowsiness, and severe adynamia. On examination he was found to be bradypsychic and areflexic. On January 19, 2020, he was referred to a hospital in Piura diagnosed with encephalitis; he stayed one day and then his family members took him to a more complex hospital, where a lumbar puncture was carried out and showed hematic CSF, he was diagnosed with liver failure and encephalitis, and died one day later at home.

The third case was a six-year-old boy, with history of seizures from the age of six months to three years. In October

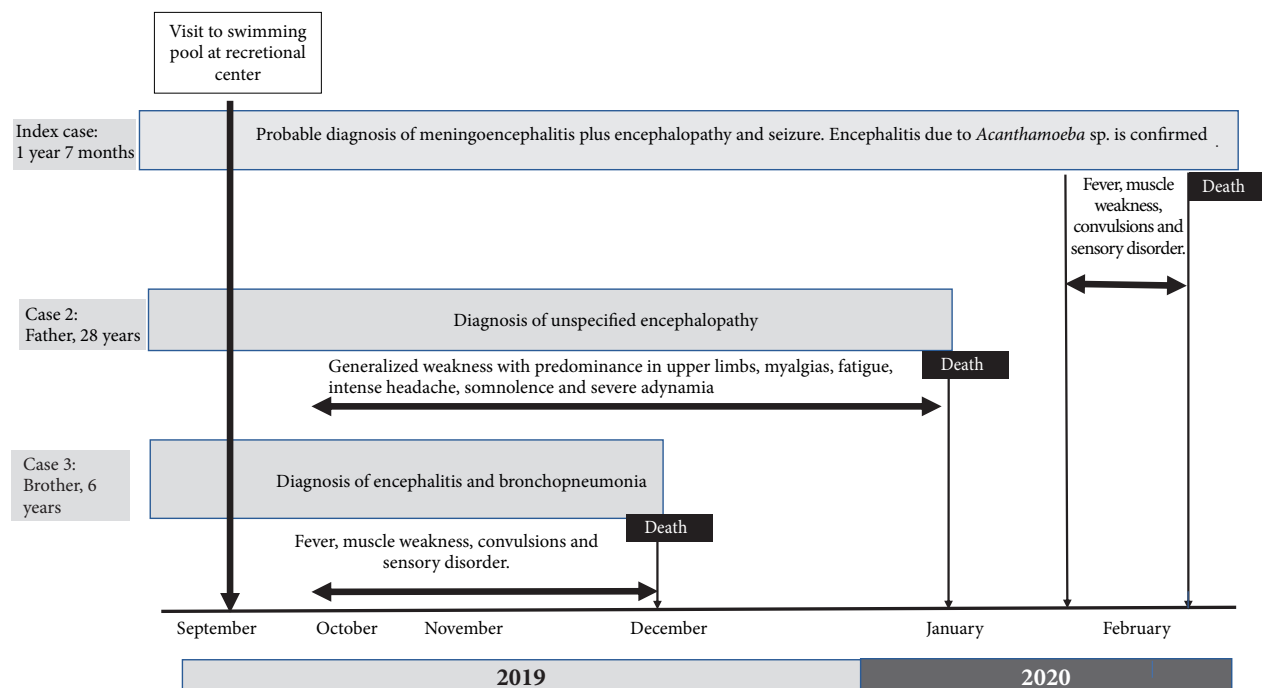


Figure 1. Timeline of cases. Lethal encephalitis due to free-living amoebae in three members of a family, in Tumbes, Peru.

2019 he presented severe headache radiating to the back, dizziness, and insomnia. He was evaluated at the local health facility, where he received analgesics. The patient had a “fixed gaze”, unsteadiness, loss of muscle tone and temporary unconsciousness. On November 8, 2019, he had fever (39-40 °C), intensified headache, incoherent speech, ataxia, loss of strength in lower limbs, right eye deviation and seizures. He was evaluated at the local hospital, where dysarthria and left hemiparesis were found; he was presumptively diagnosed with malignant brain tumor. On November 9, 2019, he was hospitalized and received treatment for autoimmune encephalitis. During hospitalization, he was also diagnosed with healthcare-associated infection. He died in December 2019. No additional examinations were conducted, and no necropsies were carried out for any of the cases.

Field research

The patients had not traveled in recent years and had not had contact with sick people or animals. Their home had water and indoor sewage. Cutaneous mycosis in the left malar region was reported in case 3 and tinea capitis in case 2. A visit to a public swimming pool was reported in September 2019, where only the three cases entered the pool. The institutional and community search did not find similar diagnoses or people who met the case definition.

The private swimming pool is located 15 minutes by car from the locality of the cases’ residence and has four concrete pools with no water circulation system or operating license. The employees were unaware of any pool treatment methods.

DISCUSSION

This study presents three cases of encephalitis by FLA with fatal outcome in a family cluster in the department of Tumbes, with exposure to public swimming pools. This is the first report of a family cluster diagnosed with encephalitis by FLA in Peru; to our knowledge, an outbreak of these characteristics had not been reported anywhere in the world.

The diagnosis of disease by FLA is difficult due to the non-specific clinical characteristics that lead to dismiss the disease as a differential diagnosis ⁽¹¹⁾; in the first case, diagnosis was late and only the history of common exposure led to presume the etiology.

The clinical features in the second and third cases correspond to the classic presentation of GAE by *Acanthamoeba*. Other studies point out that the symptomatology of GAE simulates a brain tumor ⁽¹¹⁻¹³⁾, which delays the diagnosis.

Acanthamoeba infections in humans have a mortality rate of 96-98%^(14,15); therefore, it is necessary to include it among differential diagnoses. It is also important to inquire about previous history of exposure to recreational water or contact with dirty water or soil, especially if the cases come from areas with ideal climatic and sanitation conditions for the presence of *Acanthamoeba*⁽¹²⁾.

Cases of infection without a clear history of exposure have been reported, considering the distribution of FLA in soil and water, there are multiple possibilities for contact with humans, as shown by several studies that have determined the presence of antibodies against *Acanthamoeba* in healthy people^(16,17), which indicates that mainly immunosuppressed people develop the disease. Chappell *et al.* describes that the levels of antibodies are decreased 14 times in Hispanics, in consequence, this population is susceptible to this infection⁽¹⁸⁾. However, there are authors who point out that in the population of the coast of Peru (mainly Piura and Lima) there are 30% of healthy people with genotype T-4 *Acanthamoeba* in nasal mucosa^(10,19). Patients with a weakened immune system are expected to become infected and develop a lethal form of the disease. In this case series, patients had conditions such as prematurity, anemia, previous history of seizures, tinea capitis and repeated UTI.

In Peru, contamination with FLA has been found in public pools and hot springs, especially in the crowded ones, as well as in stagnant water^(11,16). Real microbiological control cannot be achieved because of the technological and economic difficulties of sanitation companies to guarantee water treatment⁽²⁰⁾. Some recreational pool administrators are personnel with a low educational level. This contributes to their lack of awareness of the importance of microbiological control in these water sources.

The possibility of diagnosing encephalitis by FLA is limited in Peru. Tumbes does not have laboratories or personnel with diagnostic capacity. The most effective approach at the moment is to take samples and send them to the few specialized laboratories in the country.

It has been documented that diagnostic imaging shows single or multiple lesions in the brain correlated with significant edema and multiple hemorrhagic areas^(4,13); the CSF characteristics in the second case could indicate hemorrhage, given the evolution of the clinical picture.

Several medications had successful results in some patients; but there is no consensus regarding the medications for GAE by *Acanthamoeba*, so combinations of 4 and 5 antibiotics are recommended, where the most effective are

miltefosine, azoles, pentamidine and cotrimoxazole⁽¹⁵⁾. It is also recommended to start antimicrobial treatment as soon as possible; however, an effective treatment for infections has not been established, since the best method of drug administration to the central nervous system (CNS), the pathophysiological mechanisms, the role of environmental conditions and the individual's genetics, as well as the immune response, are still unclear.

The main limitation of this study was the non-confirmation of *Acanthamoeba* in the second and third cases. In all of them there was a history of exposure to a swimming pool months before the disease. Due to the temporality of the exposure, *Acanthamoeba* can be related to all of them. Data regarding the clinical picture and chronology of the manifestations were obtained from interviews with relatives and may have temporal variation.

Postmortem sampling allowed the etiological diagnosis and the implementation of temporary sanitary and environmental control measures in public swimming pools in Tumbes.

In conclusion, this study describes an outbreak of encephalitis by FLA in three members of a family in Tumbes with fatal outcome. The exhaustive interrogation and rapid identification of the causal agent was essential, so encephalitis by FLA should be considered as a differential diagnosis in areas with conditions that favor its presence. It is a challenge to identify the causal agent with the usual methods available in Peru.

Permanent surveillance of water quality by health authorities and monitoring of public swimming pools are recommended. The authorized operation of swimming pools should be supervised, guaranteeing the use of disinfection, circulation, and water recirculation systems, as well as strengthening health education in the population.

Funding: This research was carried out as part of the technical assistance provided by the Centro Nacional de Epidemiología, Prevención y Control de Enfermedades (National Center for Epidemiology, Disease Prevention and Control) to the Dirección Regional de Salud (DIRESA) Tumbes.

Conflicts of interest: The author declares that she has no conflicts of interest.

Authorship contributions: MESC conceived and designed the article; collected the results; analyzed and interpreted the data; drafted the article; made a critical revision of the article; approved its final version; acquired the study material.

Acknowledgments: To the staff of the Epidemiology Directorate of DIRESA Tumbes and EsSalud for their support in the investigation of the cases.

REFERENCES

1. Visvesvara GS, Moura H, Schuster FL. Pathogenic and opportunistic free-living amoebae: *Acanthamoeba* spp., *Balamuthia mandrillaris*, *Naegleria fowleri*, and *Sappinia* diploidea. *FEMS Immunol Med Microbiol.* 2007;50(1):1-26. doi: 10.1111/j.1574-695X.2007.00232.x.
2. Ong TYY, Khan NA, Siddiqui R. Brain-Eating Amoebae: Predilection Sites in the Brain and Disease Outcome. *J Clin Microbiol.* 2017;55(7):1989-97. doi: 10.1128/JCM.02300-16.
3. Castrillón JC, Orozco LP. *Acanthamoeba* spp. as opportunistic pathogens parasites. *Rev Chilena Infectol.* 2013;30(2):147-55. doi: 10.4067/S0716-10182013000200005.
4. Walochnik J, Aichelburg A, Assadian O, Steuer A, Visvesvara G, Vetter N, et al. Granulomatous amoebic encephalitis caused by *Acanthamoeba* amoebae of genotype T2 in a human immunodeficiency virus-negative patient. *J Clin Microbiol.* 2008;46(1):338-40. doi: 10.1128/JCM.01177-07.
5. Scruggs BA, Quist TS, Salinas JL, Greiner MA. Notes from the Field: *Acanthamoeba* Keratitis Cases - Iowa, 2002-2017. *MMWR Morb Mortal Wkly Rep.* 2019;68(19):448-9. doi: 10.15585/mmwr.mm6819a6.
6. Garajová M, Mrva M. Amoebae of the genus *Acanthamoeba*--causative agents of human infections. *Epidemiol Mikrobiol Imunol.* 2011;60(3):121-30.
7. Martinez AJ. Free-Living Amebas: *Naegleria*, *Acanthamoeba* and *Balamuthia*. En: Baron S, editor. *Medical Microbiology* [Internet]. 4th ed. Galveston (TX): University of Texas Medical Branch at Galveston; 1996 [cited on February 7, 2021]. Available at: <http://www.ncbi.nlm.nih.gov/books/NBK7960/>
8. Mittal N, Mahajan L, Hussain Z, Gupta P, Khurana S. Primary amoebic meningoencephalitis in an infant. *Indian J Med Microbiol.* 2019;37(1):120. doi: 10.4103/ijmm.IJMM_18_371
9. Martinez AJ, Visvesvara GS. Free-living, Amphizoic and Opportunistic Amebas. *Brain Pathol.* 1997;7(1):583-98. doi: 10.1111/j.1750-3639.1997.tb01076.x.
10. Cabello-Vílchez AM. *Balamuthia mandrillaris* en el Perú, lesiones cutáneas, meningoencefalitis y métodos de cultivo. *Infectio.* 2016;20(2):107-19. doi: 10.1016/j.infect.2015.10.006.
11. Orrego-Puelles E, Casavilca S, Rodríguez FJ, Pritt BS, Castillo M, Castañeda CA. Amebiasis del sistema nervioso central: reporte de seis casos en el Perú. *Rev Peru Med Exp Salud Pública.* 2015;32(3):591-7.
12. Martinez AJ. Infection of the Central Nervous System Due to *Acanthamoeba*. *Rev Infect Dis.* 1991;13 (Supplement_5):S399-402. doi: 10.1093/clind/13.supplement_5.s399.
13. Ofori-Kwakye SK, Sidebottom DG, Herbert J, Fischer EG, Visvesvara GS. Granulomatous brain tumor caused by *Acanthamoeba*: Case report. *J Neurosurg.* 1986;64(3):505-9. DOI: 10.3171/jns.1986.64.3.0505.
14. Vélez VMC, Zapata SAL, Ortiz MDC, Trujillo HM, Restrepo GA, Garcés SC. Reporte de caso y revisión de la literatura de caso de paciente con meningoencefalitis por amebas de vida libre. *Infectio.* 2013;17(3):153-9. doi: 10.1016/S0123-9392(13)70722-7.
15. Mendiola J, Fresco Y, Rodríguez M. Encefalitis por amebas de vida libre: herramientas actuales para el diagnóstico y tratamiento tempranos diagnóstico y tratamiento tempranos. *Rev Cubana Med Trop [Internet].* 2020;72(3). e490.
16. Garaycochea M del C, Beltrán M, Morón C. Patogenicidad de las amebas de vida libre aisladas de fuentes de agua en Lima. *Rev Per Med Exp Salud Publica.* 2008;25(2):204-7.
17. Oddó B D. Infecciones por amebas de vida libre.: Comentarios históricos, taxonomía y nomenclatura, protozoología y cuadros anatómo-clínicos. *Rev Chilena Infectol.* 2006;23(3):200-14. doi: 10.4067/S0716-10182006000300002.
18. Chappell CL, Wright JA, Coletta M, Newsome AL. Standardized method of measuring *acanthamoeba* antibodies in sera from healthy human subjects. *Clin Diagn Lab Immunol.* 2001;8(4):724-30. doi: 10.1128/CDLI.8.4.724-730.2001.
19. Suárez R, Olaya J, Huapaya P, Náquira C. Aislamiento de *Acanthamoeba* en pacientes del Servicio de Oftalmología del Hospital Nacional Cayetano Heredia. *An Fac med.* 2002;63(4):269-74. doi: 10.15381/anales.v63i4.1507.
20. Villena Chávez JA. Calidad del agua y desarrollo sostenible. *Rev Peru Med Exp Salud Publica.* 2018;35(2):304-8. doi: /10.17843/rp-mesp.2018.352.3719.