

First genetic characterization of human cystic echinococcosis in Uruguay

Elisa Figueredo,¹ Vanessa Liporace,¹ Gustavo Mourglia-Ettlin,² Héctor Gabriel Avila,³
Daniel Da Rosa¹ and Mara Rosenzvit⁴

Suggested citation Figueredo E, Liporace V, Mourglia-Ettlin G, Avila HG, Da Rosa D, Rosenzvit M. First genetic characterization of human cystic echinococcosis in Uruguay. *Rev Panam Salud Publica.* 2022;46:e177. <https://doi.org/10.26633/RPSP.2022.177>

ABSTRACT

Cystic echinococcosis is endemic and hyperendemic in Uruguay. The objective of this study was to determine the species and genotype of *Echinococcus granulosus sensu lato* in symptomatic patients with cystic echinococcosis who underwent surgery, together with the location and stage of the cysts. The study included 13 patients aged between 6 and 57 years old. Samples of cysts from these cases were analyzed using DNA extraction, polymerase chain reaction amplification and sequencing. The results revealed the presence of *E. granulosus sensu stricto* in all cases, with 12 samples belonging to the G1 genotype and 1 to the G3 genotype, suggesting that disease persistence might be related to the dog–sheep cycle. However, other intermediate hosts, such as cattle, could also be involved. Cysts were most frequently found in the liver, followed by muscle and other sites (e.g. pulmonary, vertebral, pelvic and cardiac); and stage CE1 was most frequently found, followed by CE2 and CE3b. Three cases occurred in children or adolescents, suggesting an active parasite cycle in at least some areas of the country. Since there is considerable diversity of *E. granulosus sensu lato* species and genotypes in South America, it is important to continue the present study in order to draw stronger epidemiological conclusions.

Keywords

Echinococcosis; genotypes.

Cystic echinococcosis (CE) is one of the most serious parasitic diseases in humans, ranking second in the list of foodborne parasites worldwide. Additionally, it is included in the list of 17 neglected tropical diseases prioritized by the World Health Organization (1).

The etiological agent of CE is the cestode *Echinococcus granulosus sensu lato* (s.l.), which is a complex of species with great genetic and phenotypic variation, and its taxonomy is still controversial (2). In recent years, phylogenetic analyses based on mitochondrial genes have allowed for the classification of most of the genotypes as new species (3). Numerous studies have suggested that *E. granulosus* s.l. is a complex of five species: *E. granulosus sensu stricto* (s.s.), including genotypes G1 and G3; *E.*

equinus (G4); *E. ortleppi* (G5); *E. canadensis* (G6–G8 and G10); and *E. felidis* (2, 3). Additionally, a new genotype has been discovered in Ethiopia, adding even more complexity to the molecular taxonomy of this parasite (4).

Worldwide, many isolates from human cases of CE have been genotyped, with *E. granulosus* s.s. being the species most frequently found in patients, followed by *E. canadensis* and *E. ortleppi* (5). So far, only one human case of *E. equinus* (G4) infection has been recorded, suggesting that this species and genotype has low infectivity in humans (5).

In Argentina, Brazil, Chile, Bolivia (Plurinational State of) and Peru, the genotypes most often found in humans are G1 (72.3%) and G6 (21.3%) (6). Human cases due to genotypes G3,


¹ Departamento de Parasitología y Micología, Facultad de Medicina, Universidad de la República, Montevideo, Uruguay ✉ Daniel Da Rosa, danddr@gmail.com

² Área Inmunología del Departamento de Biociencias, Facultad de Química, Universidad de la República, Montevideo, Uruguay

³ Laboratorio Provincial de Zoonosis, Ministerio de Salud de la Provincia de San Juan, San Juan, Argentina

⁴ Instituto de Investigaciones en Microbiología y Parasitología Médica, Facultad de Medicina, Universidad de Buenos Aires, Buenos Aires, Argentina

FIGURE 1. Multiple sequence alignment of *cox1* samples obtained from 13 patients with human cystic echinococcosis reported in this study (numbers 1–13) with *cox1* reference sequences from each species and genotype used as references (7)



Source: Figure prepared by the authors with data from this study.

G5 and G7 have also been reported, but are less common (6, 7). Unfortunately, although programs for echinococcosis control in Uruguay have been in place since 1973, there are no current data about *E. granulosus* s.l. species and genotypes for Uruguayan patients. Scarce information about parasite genotypes and species have been reported for cattle, with *E. granulosus* s.s. (G1) and *E. ortleppi* (G5) the only two genotypes found to date (6).

Using molecular identification in human cases of CE is recommended to obtain a better understanding of the epidemiology, pathology and course of infection. This is particularly important

in areas where multiple etiological agents overlap (8). In 2005, the CE control policies in Uruguay were redefined, and disease control and surveillance are now focused on providing care at the primary health care level, in communities where dogs with echinococcosis are observed and in high-risk areas (9). The aim of the present study was to determine the species and genotypes of *E. granulosus* s.l. infections in human cases of CE in Uruguay and to characterize the infection in terms of the patient’s age, and the location and stage of the CE cysts. The study was conducted from March 2015 through March 2019.

MATERIALS AND METHODS

An observational descriptive study was performed between March 2015 and March 2019 in Uruguay. The collection and analyses of CE cysts were performed with the informed consent of the patients and the approval of the ethics committee of the Faculty of Medicine, Universidad de la República, Uruguay. Samples from cysts were obtained from all 13 patients undergoing surgical treatment in public and private hospitals throughout Uruguay. Patients were diagnosed clinically or by imaging, or both, and surgery was the treatment of choice for all 13 cases.

Samples were obtained from each cyst by the surgeon immediately after surgery, and refrigerated germinal and laminated layers or cyst fluids, or a combination of these, were sent to our laboratory within 4 hours. Data on the age, sex and state and place of birth of the patients and their geographical area of residence during childhood were recorded, as well as the location and stage of the cyst. Samples were stored in 70% ethanol at 4 °C.

Genomic DNA was extracted from protoscoleces or the germinal layer (in those cysts with no protoscoleces) using the DNeasy Blood & Tissue Kit (QIAGEN, Germany) according to the manufacturer’s instructions. The DNA was stored at -20 °C until undergoing amplification by polymerase chain reaction (i.e. PCR). For the molecular identification of *E. granulosus* s.l. genotypes, a 444 bp fragment of the *cox1* gene was amplified, as previously described by Bowles et al. (10), with some modifications made according to Cucher et al. (5).

Amplification products were purified by ethanol precipitation and then sent to Macrogen (Seoul, Republic of Korea) for sequencing in both directions.

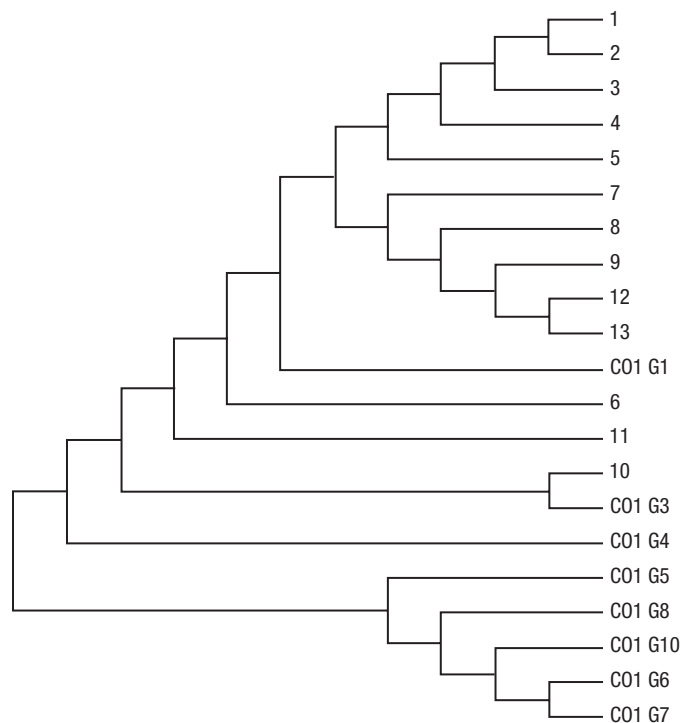
The sequences obtained were then aligned and compared with the reference sequences of *E. granulosus* s.l. downloaded from the GenBank database (accession numbers: M84661 [G1], M84662 [G2], M84663 [G3], M84664 [G4], M84665 [G5], M84666 [G6], M84667 [G7], AB235848 [G8] and AF525457 [G10]), using BioEdit 7.2.5 software for Windows (BioEdit Ltd., Manchester, United Kingdom); they were manually edited with Chromas software (Technelysium, South Brisbane, Australia). Phylogenetic analyses were performed using the maximum likelihood method; the evolutionary story was inferred using the maximum probability method, based on the 1993 Tamura–Neil model. The phylogenetic tree was constructed from 500 replicates to represent the evolutionary history of the analyzed taxa using MEGA6: Molecular Evolutionary Genetics Analysis version 6 software (MEGA Software).

To ensure the anonymity of patients, a database was built consisting only of the sample number, the age of the patient, the location of the cyst, the stage of the disease and the results of genotyping. Surgeons obtained informed consent from patients after describing the aims of the study and the use of the samples. The authors adhered to the journal’s standards for informing patients and preserving their anonymity.

RESULTS AND DISCUSSION

The methods used in this study ensured that the samples were adequately preserved during transfer to the laboratory and were processed in <4 hours. Samples of CE cysts were obtained from 10 male and 3 female patients aged between 6 and 57 years (10 adults and 3 children). Six cysts were in the liver, three in muscle, one in the lungs, one was vertebral, one

FIGURE 2. Maximum likelihood tree of isolates from cysts from 13 patients with human cystic echinococcosis analyzed in this study (numbers 1–13) and reference sequences of *Echinococcus granulosus sensu lato* species and genotypes



Source: Figure prepared by the authors with data from this study.

in the pelvic area and one in the heart. In total, 12 samples belonged to the G1 genotype and 1 to the G3 genotype.

Nine cysts were classified as stage CE1, three were CE2 and one was CE3b. All were resolved by surgery, and resolution was confirmed by parasitological and histopathological examinations.

All adult patients shared the epidemiological link of a rural childhood. However, some of the children and adolescents resided in the suburbs. Thus, various environmental factors may also be responsible for disease transmission, such as the migration of populations from rural to suburban areas, which may contribute to the disease spreading to previously unaffected areas.

The presence of cases in children and adolescents indicates there is active transmission in different parts of the country. Younger individuals may be at higher risk due to greater exposure to dogs, a finding that has been observed in other research (11). The situation of echinococcosis in Uruguay is worrying because information about environmental exposure is scarce and because counting only hospital admissions and discharges attributed to the International Statistical Classification of Diseases and Related Health Problems, tenth revision (ICD-10), code B67 may not reflect the actual number of cases in the country.

Not only is CE an important public health problem, resulting in costs associated with the diagnosis, treatment and hospitalization of patients, but also it causes economic losses, for example, due to confiscation of infected cattle viscera and production losses (12).

Phylogenetic analyses showed that all cases were due to infection with *E. granulosus* s.s. (Figures 1 and 2). These findings

are consistent with the high prevalence of *E. granulosus* s.s. in humans both worldwide (7) and in South America (5).

The results obtained here suggest that the persistence of the disease could be due to the dog–sheep cycle, which is perpetuated when raw sheep offal is fed to dogs, thus completing the cycle. However, bovine transmission cannot be ruled out since *E. granulosus* s.s. can produce fertile cysts in cattle in South America (7).

The proportion of new cases in children younger than 15 years indicates that transmission has not been interrupted. Therefore, the observed cases indicate that there is an active cycle in our country, despite control programs being implemented the 1960s (13).

Due to the diversity of species and genotypes existing in the Region of the Americas and given the implications that these findings could have for CE control programs, it is important to continue the present study to gain a better understanding of the epidemiology of CE in Uruguay. Additionally, new data about the molecular epidemiology of *E. granulosus* s.l. might aid in addressing additional questions, such as why there is variability in the response to treatments and why cysts appear in unusual locations.

Authors' contributions. DDR and EF had the original idea for and planned the experiment. EF, VL, HGA and MR analyzed and interpreted the results. DDR, GME and EF wrote the paper. MR, GME, HGA and DDR supervised, reviewed and edited the paper. All authors reviewed and approved the final version.

Acknowledgments. The authors thank the members of the surgical services of the participating hospitals who helped us during the study.

Conflicts of interest. None declared.

Funding. This study was supported by funding from the Research Initiation Program of the Sectoral Commission for Scientific Research, Universidad de la República, Uruguay. The sponsors had no influence on the design of the study, the data collection and analysis, the writing and the decision to publish this article.

Disclaimer. Authors hold sole responsibility for the views expressed in the manuscript, which may not necessarily reflect the opinion or policy of the *Revista Panamericana de Salud Pública*/*Pan American Journal of Public Health* or the Pan American Health Organization (PAHO).

REFERENCES

1. World Health Organization. Multicriteria-based ranking for risk management of food-borne parasites: report of a Joint FAO/WHO expert meeting. Rome: Food and Agriculture Organization of the United Nations, World Health Organization; 2014. <https://apps.who.int/iris/handle/10665/112672>
2. Romig T, Ebi D, Wassermann M. Taxonomy and molecular epidemiology of *Echinococcus granulosus sensu lato*. *Vet Parasitol*. 2015;213:76-84.
3. Nakao M, Yanagida T, Okamoto M, Knapp J, Nkouawa A, Sako Y, et al. State-of-the-art *Echinococcus* and *Taenia*: phylogenetic taxonomy of human-pathogenic tapeworms and its application to molecular diagnosis. *Infect Genet Evol*. 2010;10:444-52.
4. Kinkar L, Laurimäe T, Sharbatkhori M, Mirhendi H, Kia EB, Ponce-Gordo F, et al. New mitogenome and nuclear evidence on the phylogeny and taxonomy of the highly zoonotic tapeworm *Echinococcus granulosus sensu stricto*. *Infect Genet Evol*. 2017;52:52-8.
5. Cucher MA, Macchiaroli N, Baldi G, Camicia F, Prada L, Maldonado L, et al. Cystic echinococcosis in South America: systematic review of species and genotypes of *Echinococcus granulosus sensu lato* in humans and natural domestic hosts. *Trop Med Int Health*. 2016;21:166-75.
6. Macin S, Orsten S, Samadzade R, Colak B, Cebeci H, Findik D. Human and animal cystic echinococcosis in Konya, Turkey: molecular identification and the first report of *E. equinus* from human host in Turkey *Parasitol Res* 2021;120:563-8.
7. Avila HG, Santos GB, Cucher MA, Macchiaroli N, Pérez MG, Baldi G, et al. Implementation of new tools in molecular epidemiology studies of *Echinococcus granulosus sensu lato* in South America. *Parasitol Int*. 2017;66:256-7.
8. Ito A, Nakao M, Lavikainen A, Hoberg E. Cystic echinococcosis: future perspectives of molecular epidemiology. *Acta Trop*. 2017;165:3-9.
9. Irabedra P, Ferreira C, Sayes J, Elola S, Rodríguez M, Morel N, et al. Control programme for cystic echinococcosis in Uruguay. *Mem Inst Oswaldo Cruz*. 2016;111:372-7.
10. Bowles J, Blair D, McManus DP. Genetic variants within the genus *Echinococcus* identified by mitochondrial DNA sequencing. *Mol Biochem Parasitol*. 1992;54:165-74.
11. Rasib Q, Khan A, Ahmed H, Nizamuddin S, Asif F, Afzal MS, et al. Demographics of cystic echinococcosis patients treated surgically in Lahore, Pakistan: a single centre study from 2007–2018. *Helminthologia*. 2021; 58:162-72.
12. Bingham GM, Larriue E, Uchiumi L, Mercapide C, Mujica G, Del Carpio M, et al. The economic impact of cystic echinococcosis in Rio Negro Province, Argentina. *Am J Trop Med Hyg*. 2016;94:615-25.
13. Pavletic CF, Larriue E, Guarnera EA, Casas N, Irabedra P, Ferreira C, et al. Cystic echinococcosis in South America: a call for action. *Rev Panam Salud Publica*. 2017;41:e42.

Manuscript submitted 19 January 2022. Revised version accepted for publication on 25 July 2022.

Primera caracterización genética de la equinocosis quística humana en Uruguay

RESUMEN

La equinocosis quística es endémica e hiperendémica en Uruguay. El objetivo de este estudio fue determinar la especie y el genotipo de *Echinococcus granulosus sensu lato* en pacientes sintomáticos con equinocosis quística que fueron sometidos a cirugía, además de la localización y estadio de los quistes. En el estudio participaron 13 pacientes de entre 6 y 57 años. Las muestras de quistes de estos casos se analizaron mediante la extracción de ADN, la amplificación de la reacción en cadena de la polimerasa y la secuenciación. Los resultados revelaron la presencia de *E. granulosus sensu stricto* en todos los casos, con 12 muestras pertenecientes al genotipo G1 y 1 muestra de genotipo G3, lo que sugiere que la persistencia de la enfermedad podría estar relacionada con el ciclo perro/ovinos. Sin embargo, otros huéspedes intermedios, como el ganado, también podrían estar involucrados. Los quistes se encontraron con mayor frecuencia en el hígado, seguido por los músculos y otros sitios (por ejemplo, quistes pulmonares, vertebrales, pélvicos y cardíacos); y el estadio más frecuente fue CE1, seguido por CE2 y CE3b. Tres de los casos ocurrieron en niños o adolescentes, lo que sugiere un ciclo activo de parásitos al menos en algunas áreas del país. Dado que existe una considerable diversidad de especies y genotipos de *E. granulosus sensu lato* en América del Sur, es importante continuar con este estudio para extraer conclusiones epidemiológicas más sólidas.

Palabras clave Equinocosis; genotipo.

Primeira caracterização genética da equinocose cística humana no Uruguai

RESUMO

A equinocose cística é endêmica e hiperendêmica no Uruguai. O objetivo do estudo foi determinar a espécie e o genótipo do *Echinococcus granulosus sensu lato* em pacientes sintomáticos com equinocose cística que foram submetidos a cirurgia, juntamente com a localização e o estágio dos cistos. O estudo incluiu 13 pacientes entre 6 e 57 anos de idade. As amostras de cistos foram analisadas utilizando extração do DNA, amplificação pela reação em cadeia da polimerase e sequenciamento. Os resultados revelaram a presença de *E. granulosus sensu stricto* em todos os casos, com 12 amostras pertencentes ao genótipo G1 e uma ao genótipo G3, sugerindo que a persistência da doença pode estar relacionada ao ciclo cão-ovelha. Entretanto, outros hospedeiros intermediários como gado também poderiam estar envolvidos. Os cistos foram mais frequentemente encontrados no fígado, seguido por músculos e outros locais (por exemplo, pulmão, vértebras, pelve e coração), e o estágio mais frequentemente encontrado foi o CE1, seguido por CE2 e CE3b. Três casos ocorreram em crianças ou adolescentes, o que sugere um ciclo parasitário ativo em pelo menos algumas áreas do país. Devido à considerável diversidade de espécies e genótipos de *E. granulosus sensu lato* na América do Sul, é importante dar continuidade do presente estudo a fim de se chegar a conclusões epidemiológicas mais sólidas.

Palavras-chave Equinocose; genótipo.
